

Transcatheter Aortic Valve Replacement for Aortic Insufficiency

Marwan Amara ^{1,2} and Yair Feld ²

1. Cardiology Department, The Baruch Padeh Medical Center (Tzafon), Poriya, Tabariya, Israel; 2. Cuspa Ltd, Caesarea, Israel

Abstract

Transcatheter aortic valve replacement (TAVR) has developed into a viable treatment for aortic regurgitation (AR), particularly in high-risk or elderly patients unable to undergo surgery. Early generation devices encountered significant challenges, including high mortality rates, residual paravalvular leaks, and complications such as valve embolisation. However, advancements in TAVR technology, including self-expanding and balloon-expandable devices, have improved procedural outcomes. Dedicated devices, such as the Trilogy system (JenaValve) and J-Valve (Edwards Lifesciences), specifically designed for AR, have demonstrated superior performance with reduced complications and better patient survival. Other devices, such as Cusper (Cuspa) and the Zeta/Alpha systems (Laguna Tech), show potential for treating complex AR cases, including those with non-calcified valves or active endocarditis. These innovations offer hope for patients with severe AR, highlighting the need for tailored approaches based on individual anatomical and pathological variations.

Keywords

Aortic regurgitation, transcatheter aortic valve replacement, dedicated devices

Received: 15 February 2025 **Accepted:** 7 October 2025 **Citation:** *Interventional Cardiology* 2025;20:e36. **DOI:** <https://doi.org/10.15420/icr.2025.06>

Disclosure: YF is the founder and director of Cuspa, Paragate Medical and HVT Medical. MA has no conflicts of interest to declare.

Acknowledgements: The authors used an AI language model for assistance with drafting the introduction and summarising key findings. The final content reflects the authors' own analysis and interpretations.

Correspondence: Marwan Amara, Cardiology Department, The Baruch Padeh Medical Center (Tzafon), Poriya, Tabariya, 1528001, Israel. E: marwan77@hotmail.it

Copyright: © The Author(s) 2025. This work is open access and is licensed under CC-BY-NC 4.0. Users may copy, redistribute and make derivative works for non-commercial purposes, provided the original work is cited correctly.

Aortic regurgitation (AR) is a common clinical issue among adults. In individuals above the age of 70 years the prevalence of at least moderate AR is estimated to be about 2.2%.¹ It is identified by the backward flow of blood from the aorta into the left ventricle (LV) during diastole due to misaligned aortic cusps.²

Although surgical aortic valve replacement (SAVR) is the recommended treatment of AR, many elderly patients are refused surgery due to high operative risk. However, if left untreated, severe aortic insufficiency with noticeable symptoms carries a high risk of death.³ Studies have shown that more than 70% of individuals with severe symptoms, categorised as New York Heart Association (NYHA) class III or IV, may not survive beyond 5 years.^{4,5}

In response to this identified need and drawing on the successful use of transcatheter aortic valve replacement (TAVR) in aortic stenosis (AS), over the past decade clinicians have been examining the potential of TAVR for AR treatment.

These studies began with early generation TAVR – CoreValve (Medtronic) and the SAPIEN valve (Edwards Lifesciences) – and demonstrated poor outcomes with high mortality, residual paravalvular leak (PVL), second valve implantation, device embolisation and the need for a pacemaker.^{6–9} These challenges and limitations occurred due to a lack of calcium, difficulty anchoring and root dilatation with large stroke volume causing malpositioning of the prosthesis and embolisation.^{10–13} The next generation of TAVR with self-expandable and balloon-expandable valves,

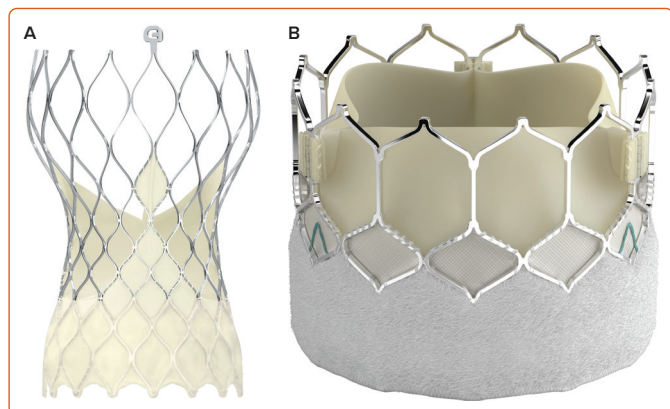
demonstrated improved outcomes but still yielded unsatisfactory results in terms of mortality and high procedural complications in high-risk patients.¹²

There is a now new generation of dedicated devices that have proven to be superior in terms of mortality and complications.^{10,14} This article reviews these devices and the evidence for their efficacy, mortality rates and limitations when used for AR.

Challenges of Transcatheter Aortic Valve Replacement in Pure Aortic Regurgitation

The application of TAVR in patients with pure native AR presents distinct technical complexities compared to its use in calcific AS. These difficulties are primarily due to the lack of calcific anchoring substrate. In contrast to AS, native pure AR typically lacks significant valvular calcification, which impairs secure anchoring of the transcatheter prosthesis within the annular plane. This absence of structural rigidity compromises the stability of the device.¹⁵ Also, patients with native AR often exhibit pronounced left ventricular hypercontractility driven by elevated stroke volume and a dynamic regurgitant jet. These factors generate substantial intraventricular turbulence, undermining precise control during valve deployment. Further, the aortic annulus in this patient population tends to be dilated, frequently surpassing the dimensions supported by commercially available transcatheter valve devices.¹⁶ This mismatch between anatomical size and prosthetic specifications further complicates procedural planning and raises the risk of valve migration and malposition, a need for surgery, PVL and valve embolisation.¹⁷

Figure 1: Evolut Pro and Sapien 3 Ultra Valves



A: Evolut Pro. B: Sapien 3 Ultra. Reproduced with permission from Medtronic (A) and Edwards Lifesciences (B).

Non-dedicated Devices

Transcatheter management of pure AR presents distinctive challenges due to the absence of annular calcification, leading to poor anchoring. To mitigate risks such as valve migration, embolisation, PVL and the need for a permanent pacemaker (PPM) implantation, operators frequently use aggressive oversizing and deeper deployment of the device. These adaptations, while necessary, increase the likelihood of annular rupture, conduction disturbances and procedural complications, resulting in higher periprocedural mortality and surgical conversion rates compared to AS cases.^{18–20}

First-generation CoreValve allowed substantial oversizing due to its nitinol frame, ensuring reasonable anchoring. However, it was associated with a 7% rate of second valve implantation and 9% incidence of moderate-to-severe PVL.¹⁹ Medtronic's Evolut series' improved sizing flexibility and sealing performance reduced PVL rates and expanded anatomical applicability. The SAPIEN 3 – first used for AR in 2016 – had a balloon-expandable design which enabled controlled oversizing of 16–27% and lower implantation. In the S3AR trial there was a 94% procedural success rate among 49 patients when using SAPIEN 3.²¹

The France TAVI and Pantheon registries demonstrated success rates between 83–85% for first-generation valves but highlighted significant rates of second valve use and high PPM incidence (22–36%).^{22,23} Four-year mortality reached 54%, illustrating the complexity of AR cases. Oversizing remains critical for device stability but poses mechanical risks. Studies have underscored the importance of routine post-dilatation to optimise valve expansion and accommodate the altered AR anatomy.^{22,23}

CoreValve and Evolut

CoreValve was the most commonly reported transcatheter heart valve (THV) used in the early generation of TAVR for AR.²⁴ The second-generation device, the Evolut, is a bioprosthesis made from a single layer of porcine pericardium mounted on a self-expanding, multi-level, radiopaque nitinol frame and is available in sizes 23 mm, 26 mm, 29 mm and 34 mm (Figure 1 and Table 1).^{25–27}

A key advantage of self-expandable devices in TAVR is the potential for oversizing with a lower risk of rupture compared to balloon-expandable valves. This design feature was intended to ensure stable anchoring within the aortic annulus, even in the absence of significant calcium.¹² The earliest study by Roy et al. in 2013 included 43 patients treated with the

first-generation CoreValve.⁸ While demonstrating a 97% procedural success rate, the study reported several adverse outcomes: 19% of patients required a second valve procedure, 21% experienced more than mild residual AR, 5% suffered a major stroke and 9% had 30-day mortality. These findings were corroborated by other early studies. Testa et al. reported an 80% procedural success rate but a 23% 30-day mortality.⁹ Similarly, Ferker et al. observed a 77% implantation success rate but a 36% 1-year mortality.²⁸ These initial results underscored the significant risks associated with early TAVR for AR, particularly with first-generation devices.

The latest Evolut design includes new features: an extended pericardial skirt, which reduces the risk of PVL; higher radial force, which gives more consistency across annular sizes; a shorter frame height of 45 mm which reduces the risk of malpositioning; it is recapturable before full deployment; and has enhanced cell geometry, which makes it fit better in elliptical or asymmetric annuli.²⁹ These new features guarantee better performance and achieve higher implantation, while reducing the risk of PVL and embolisation in the aorta. The risk of PPM implantation is also reduced when implantation is at 3–5 mm.¹²

SAPIEN

The SAPIEN 3 and its successor, the SAPIEN 3 Ultra, have been studied extensively in the context of aortic insufficiency. It consists of a balloon-expanding, radiopaque frame made of cobalt-chromium alloy and a tri-leaflet bovine pericardial tissue valve, available in sizes 20 mm, 23 mm, 26 mm and 29 mm (Figure 1 and Table 1).³⁰

During 2015–2021, the S3AR trial included 37 patients with pure native AR with no calcium. A 29 mm SAPIEN was used in most cases and the device had a near 95% success rate. There were four cases of embolisation that were treated with surgery or implantation of Evolut. All four cases had oversizing of less than 15%. Analysing the results, the authors recommended oversizing the valve by 15% and positioning it lower than for AS to achieve better anchoring.³¹ However, there was a high rate of conduction defects, with six patients (16%) requiring pacemaker implantation.

Similar rates were seen in other studies (including first- and second-generation devices).^{11,12}

Myval System

The Myval system (Meril Life Sciences) became commercially available in Europe in 2021 (Figure 2 and Table 1). It features a cobalt alloy-framed hexagon design in a hybrid honeycomb structure. This structure consists of open cells (53%) at the aortic end and closed cells (47%) at the ventricular end, which provide impressive annular radial force.³² It offers a range of sizes: conventional sizes 20 mm, 23 mm, 26 mm and 29 mm; intermediate sizes 21.5 mm, 24.5 mm and 27.5 mm; and extra-large sizes 30.5 mm and 32 mm.³³

The Myval Octacor THV is the new version of the balloon-expandable Myval THV. In contrast to its predecessor, the novel device design incorporates only two rows of identical octagonal cells.³⁴ The 32 mm Myval THV covers annulus dimensions up to a perimeter of 100.53 mm and was recently implanted successfully in a patient with active endocarditis with central perforation of a heart valve leaflet.³⁵

Recent meta-analyses have reported on the use of Myval in non-calcified AR, including 911 patients treated with TAVR for AR. The device

Table 1: Summary of Devices Available for Transcatheter Aortic Valve Implantation in Pure Aortic Regurgitation

Device	Mechanism	Sizes (mm or S/M/L)	Status	Results in Aortic Regurgitation ^{25,26}
Evolut Pro (Medtronic)	<ul style="list-style-type: none"> Self-expanding nitinol frame Supra-annular placement Oversizing and deeper implantation Transfemoral access 	23, 26, 29, 34	Off label (Europe)	Success rate: 76–84% 30-day mortality: 6–8% Valve embolisation: 13.6% Surgical conversion: 5–10%
SAPIEN 3 Ultra (Edwards Lifesciences)	<ul style="list-style-type: none"> Balloon-expandable frame Outer sealing skirt Transfemoral access Positioned intra-annularly Oversizing to increase radial force 	20, 23, 26, 29	Off label (US, Europe)	Success rate: 76% 30-day mortality: 5–7% Valve embolisation: 10% Surgical conversion: 5–8%
Trilogy system (JenaValve)	<ul style="list-style-type: none"> Self-expanding nitinol frame Locator technology Sealing ring Transfemoral access 	S, M, L	On label Approved (Europe)	Success rate: 95% 30-day mortality: 1.4% Valve embolisation: <2% Surgical conversion: <2%
J-Valve (Edwards Lifesciences)	<ul style="list-style-type: none"> Self-expanding nitinol stent frame Three U-shaped anchor rings Automatic leaflet grasping Transfemoral/apical access 	22, 25, 28, 31, 34	Approved (China, Europe) Compassionate use (US)	Success rate: 93% 30-day mortality: <5% Valve embolisation: <2% Surgical conversion: <2%
Myval THV (Meril Life Sciences)	<ul style="list-style-type: none"> Balloon-expandable valve Commissural posts Transfemoral access 	20, 21.5, 23, 24.5, 26, 27.5, 29, 30.5, 32	Off-label (India)	Success rate: 94% 30-day mortality: 5.3% Valve embolisation: 3.5% Surgical conversion: NA
The Cusper (Cuspa Medical)	NA	NA	<i>Ex-vivo</i> and porcine models (pre-clinical stage) First-in-human trials (2025)	
The Alpha and Zeta valve (Laguna Tech)	<ul style="list-style-type: none"> Self-expanding (Alpha) Balloon-expanding (Zeta) 	NA	In-human clinical trials	

success rate was found to be 80.4%, the 30-day mortality was 9.5%, 7.4% had more than moderate AR, and 3% required conversion to open surgery.³⁶

A 2023 retrospective study in Spain evaluated the Myval in 113 non-operable patients with a mean Society of Thoracic Surgeons Predicted Risk of Mortality (STS-PROM) score of $2.7 \pm 1.7\%$. Most patients (84.1%) received extra-large valves, with an average oversizing of $17.9 \pm 11.0\%$. The procedure was technically successful in 94.7% of cases. Post-procedure, 8.9% of patients had moderate or greater AR and 22.2% required a pacemaker. Valve embolisation occurred in four patients (3.5%) and 30-day and 1-year mortality rates were 5.3% and 9.7%, respectively. The study concluded that Myval is a viable and safe treatment option for selected non-operable patients with native non-calcified aortic rings, exhibiting favourable mid-term results.³⁷

While these results may appear less favourable compared to success rates for AS, this device still offers the potential advantage of covering a large area – up to 32.7 mm – a capability that is not supported by the dedicated JenaValve.^{38,39}

Limitations and Precautions of Using Off-Label Devices in Aortic Regurgitation

Performing TAVR in AR, especially when using off-label devices, requires a comprehensive, multidisciplinary heart team approach. The decision-making process must incorporate detailed anatomical assessment, technical feasibility and contingency planning for potential complications, including the need for mechanical circulatory support or emergency surgical intervention.

For example, oversizing is often necessary in AR due to the lack of annular calcification and frequent aortic root dilation. However, it carries both acute and chronic risks. Immediate risks include aortic root rupture, valve embolisation and the need for emergency cardiopulmonary bypass; long-term risks include paravalvular leak, leaflet trauma and reduced valve durability.

These risks underscore the importance of precise sizing, optimal valve positioning and being prepared for post-dilatation or second-valve implantation.⁴⁰ Several clinical algorithms assist cardiologists in guiding patients toward SAVR or TAVR. Key predictive criteria include:

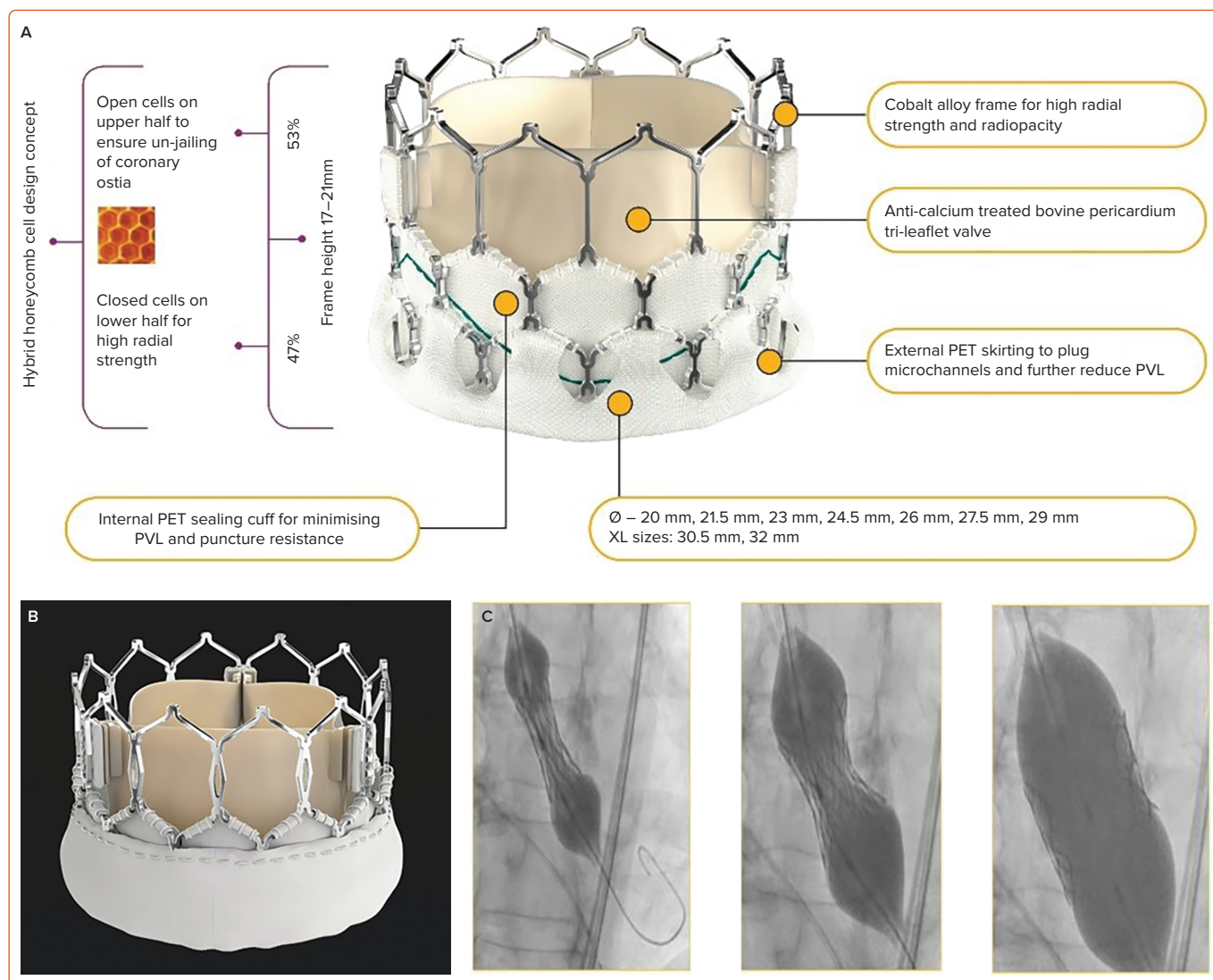
- serum albumin levels;
- STS-PROM score >8%
- major vascular disease;
- moderate or greater baseline mitral regurgitation;
- left ventricular ejection fraction $\leq 45\%$;
- stage 2 acute kidney injury; and
- pre-existing left bundle branch block.¹²

These factors help stratify procedural risk and inform shared decision-making, accordingly, to the availability of purpose-built THVs.

Effective TAVR planning in AR relies on individualised anatomical assessment to anticipate technical challenges and select the most suitable THV. Key anatomical considerations include:

- valve morphology (bicuspid versus tricuspid);
- annular dimensions and leaflet calcification;

Figure 2: Myval Valves



A: Myval THV. B: Myval Octacor. C: Balloon-expanding mechanism. PET = polyethylene terephthalate; PVL = paravalular leak. Reproduced with permission from Meril Life Sciences.

- mechanism of AR (cusp prolapse, retraction or aortic dilation);
- left ventricular size and function, including left ventricular outflow tract (LVOT) measurements; and
- aortic root and ascending aorta dimensions.

Device Selection and Deployment Challenges

Self-expandable valves offer multiple anchoring zones but may not be big enough for large annuli. Balloon-expandable valves, such as Myval, provide broader sizing and may be preferable in oversized anatomy. A lack of fluoroscopic markers in AR complicates positioning, requiring careful imaging and pacing strategies.⁴¹ Dedicated device valves often require fast pacing (~140 BPM) during deployment, whereas balloon-expandable valves may need more rapid pacing (~220 BPM) to stabilise the valve and reduce regurgitation flow.

In cases of moderate or greater residual AR, there is a post-dilation embolisation risk and implanting a second THV may be necessary.⁴²

Anatomical Challenges

TAVR in the setting of bicuspid aortic valve (BAV) with concomitant AR is associated with substantial anatomical complexities. These include asymmetric and heterogeneous calcific deposition, non-standard annular


morphology often characterised by elliptical or eccentric geometry, and a predisposition to aortopathy, such as ascending aortic dilation or structural wall abnormalities, which collectively complicate device sizing, anchoring and procedural outcomes.⁴³ Anatomical challenges include:

- Asymmetric calcification: BAVs often have unevenly distributed calcium deposits, making it difficult to accurately size and position the TAVR device.⁴⁴
- Annulus shape and size: in BAV, the aortic annulus can be elliptical, shallow or dilated, deviating from the more predictable circular shape of tricuspid valves. This can lead to undersizing or oversizing of the TAVR device, increasing the risk of complications.⁴⁵
- Aortopathy: BAVs are often associated with aortopathy, which is a weakening and dilatation of the aorta, including the ascending aorta. This can complicate both valve implantation and long-term outcomes.⁴⁴

Dedicated Devices The Trilogy system

The Trilogy system (JenaValve) (Figure 3, Table 1) was the first THV specifically designed for severe native AR. Approved for the transapical approach in AS in 2011 and for AR in 2013, it later received approval for

Figure 3: Jena-Valve



AR = aortic regurgitation. Reproduced with permission from Trilogy System technology.

a transfemoral approach in 2019. The Trilogy system THV uses a self-expanding nitinol frame supporting a porcine pericardial leaflet.⁴⁶ It incorporates three radio-opaque locators (feelers) that engage with the native leaflets during deployment. This innovative anchoring approach eliminates the need for annular calcification or valve oversizing, allowing for precise commissural alignment and controlled implantation depth, thereby reducing the risk of valve migration into the left ventricle.⁴⁷

A key advantage of the valve's design is its dual-sealing mechanism, which is further enhanced by the inflow section being composed of 24 diamond-shaped cells. These cells act as a sealing ring, conforming to the annular anatomy to assist with device stabilisation and also preventing PVL.⁴⁷

Additionally, the valve's supra-annular position contributes to enhanced haemodynamic performance, while coronary access is optimised through the large, open cells in the top row of the THV frame, which are carefully aligned with the coronary arteries to ensure unobstructed access.⁴⁸

Although the absence of a sealing skirt may raise concerns about the risk of post-procedural PVL, this potential drawback is effectively mitigated by the sealing ring and the valve's dual-sealing mechanism.

The valve is currently available in three sizes (23 mm, 25 mm and 27 mm), which enables treatment of 66–90 mm aortic annular perimeters.⁴⁹

An initial multicentre registry evaluating early European experiences with the Trilogy system reported outcomes from 31 transapical implantations for AR across nine German centres. Procedural success was achieved in 30 of the 31 patients (97%), with one patient requiring a valve-in-valve procedure due to initial THV dislodgement. All-cause mortality rates were 13% at 30 days and 19% at 6 months. Post-procedural PVL was absent or minimal in 28 patients and mild in three. Despite the initial high success rates, 1-year follow-up revealed a high mortality rate of 20%. This may reflect the advanced stage of the disease in these patients and the potential risks associated with the transapical approach.^{50,51}

Another study by Adam et al. demonstrated a high success rate, with 98% of 58 patients experiencing successful implantation.⁵² The study population comprised older patients with a mean age of 76.5 years and a high surgical risk, as indicated by a mean STS-PROM score of 4.2%. Importantly, no valve embolisation or conversions to open-heart surgery occurred. Haemodynamic performance was excellent, with a low mean

gradient of 4.3 ± 1.6 mmHg and there was no moderate or severe PVL. The 30-day mortality rate was 1.7% and PPM was 19.6%.⁵²

The ALIGN-AR trial was a pivotal US study evaluating the Trilogy system for the treatment of AR. This prospective, multicentre, single-arm study enrolled 180 high-surgical-risk patients with symptomatic, moderate-to-severe aortic insufficiency and completed enrolment in August 2022.

Preliminary results have demonstrated outcomes comparable to those reported in the German registry.⁵³ The primary endpoint of 1-year all-cause mortality was 7.8%, meeting the pre-specified performance goal. Device success was achieved in 96.7% of patients; 30-day mortality and stroke rates were both 2.2%. The Trilogy valve exhibited excellent haemodynamics, with a mean gradient of 3.9 mmHg and a large average effective orifice area of 2.9 cm². While moderate or greater PVL rates were very low, at 0.6%, 24% of patients required a new PPM; however, for the last 60 cases, this reduced to 14%, because the insertion technique was refined (by placing locators above the nadir of the native valve cups), there was a reduction in oversizing and optimised management of conduction abnormalities.

TAVR in this cohort was associated with improvements in NYHA functional class and quality-of-life scores at 1 year compared to baseline. Long-term follow-up of these patients will continue for 5 years.⁵³ A 2024 meta-analysis by Samimi et al. focused exclusively on patients with pure native AR, excluding those with significant AS.⁵² The study compared the safety and efficacy of dedicated TAVR systems, such as the J-Valve and Trilogy system, against off-label TAVR devices originally designed for AS.

Included studies specifically targeted individuals undergoing TAVR for pure native AR and assessed a range of clinical outcomes including: 30-day all-cause mortality, device success rate, incidence of moderate residual AR, reintervention requirement, THV embolisation or migration (TVEM), PPM implantation, stroke, major bleeding, major vascular complications and all-cause mortality at 1 year.

This meta-analysis demonstrated that using dedicated devices for pure native AR yields superior clinical outcomes compared to off-label devices. Specifically, with lower all-cause mortality rates at both 30 days and 1 year post-procedure, as well as a higher rate of device success. Further, they significantly reduced the occurrence of moderate-to-severe residual AR, TVEM, PPM implantation, major bleeding and the need for reintervention within 30 days. Importantly, the incidence of stroke and major vascular complications was comparable between both groups, indicating that the improved safety profile of dedicated devices does not compromise neurological or vascular outcomes.

The study comparing transapical and transfemoral access routes found that transfemoral access was associated with a higher incidence of PPM. This increased rate may be explained by the greater manipulation required during valve positioning, which could affect the atrioventricular conduction system. One-year all-cause mortality was found to be notably higher in the transfemoral access group relative to those who underwent the procedure via the transapical approach. This difference may be attributed to the enhanced procedural precision and improved valve stability typically associated with transapical access – especially in patients with challenging anatomy. Though more invasive, the transapical route provides a more direct and controlled pathway for delivering the valve, which can be advantageous in complex cases. These benefits are especially worth considering in patients with a lower procedural risk.

J-Valve

The J-Valve consists of a self-expanding nitinol frame with bovine pericardial leaflets (*Table 1*). A polyester skirt covers the outer surface of the valve frame. Three U-shaped ‘anchor rings’ are incorporated, allowing the device to anchor in a non-calcified annulus and conform to the sinuses of Valsalva. Additionally, these anchor rings have the potential to retract the native leaflets, avoiding interference with coronary ostia and minimising the risk of leaflet perforation. The THV is not recapturable and is deployed without the use of rapid pacing. A 10% oversizing is recommended for AR procedures, with the aim of a final position that is 70% aortic and 30% ventricular relative to the annulus. It is available in five different sizes, accommodating 18–33 mm annulus diameters and 57–104 mm annulus perimeters.⁵⁴

In a 2018 Chinese study involving 43 patients across three centres, Liu et al. reported 1-year outcomes of transcatheter aortic valve implantation. Procedural success was achieved in 97.7% of cases (n=42). One-year all-cause mortality was 4.7%, disabling stroke occurred in 2.3% of patients, new PPM implantation was required in 4.7% of cases, and valve-related reintervention was necessary in 7% of patients.⁵⁵ In this study, the authors recommended considering certain anatomical features as potential relative contraindications for the J-Valve. These include bicuspid aortic valves, where suboptimal anchoring may occur due to the absence of a distinct raphe, and annular areas larger than 908 mm².

A 2023 multicentre North American study involving 27 patients between 2018 and 2022 demonstrated procedural success in 81% of cases. This success rate improved to 100% in the last 15 patients following modifications to valve design and the exclusion of patients with leaflet prolapse. At 30 days, the investigators reported one death, one stroke and three new PPMs, and 88% of patients experienced symptoms of NYHA functional class I or II.⁵⁶

Transfemoral access was used in 75% of procedures. No patient exhibited more than mild residual AR. Notably, 38% of cases were presented with an annular perimeter exceeding 85 mm, which was an exclusion criterion in the ALIGN-AR study using the Trilogy system.⁵⁶

Trilogy versus J-Valve

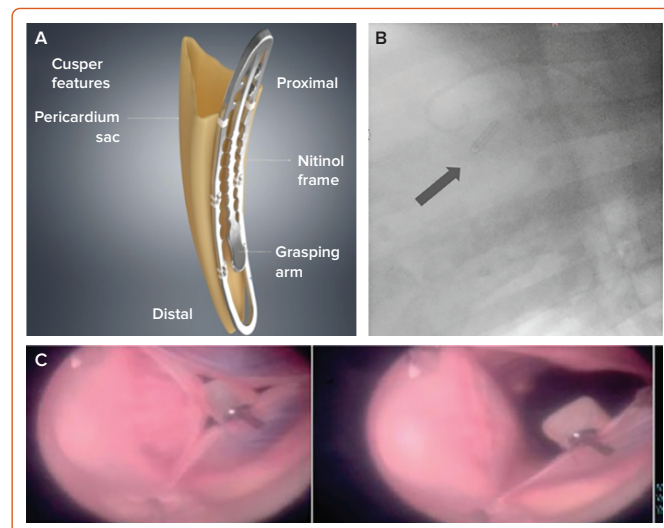
A comparison between the Trilogy system and J-Valve devices revealed that, at 30 days, the rate of PPM implantation was significantly higher in the Trilogy system group compared to the J-Valve group (21% versus 6%; $p < 0.01$). Conversely, the incidence of moderate residual AR was lower with Trilogy than with J-Valve (1% versus 3%; $p < 0.01$). This could be attributed to the Trilogy system’s distinctive anchoring design. While this mechanism excels at firmly securing the valve and reducing significant residual AR, it may inadvertently increase pressure on the heart’s conduction system. At the same time, the valve’s superior performance in minimising residual AR underscores its precision and reliability in achieving optimal placement and fit.⁵⁷

Future Devices

Cusper

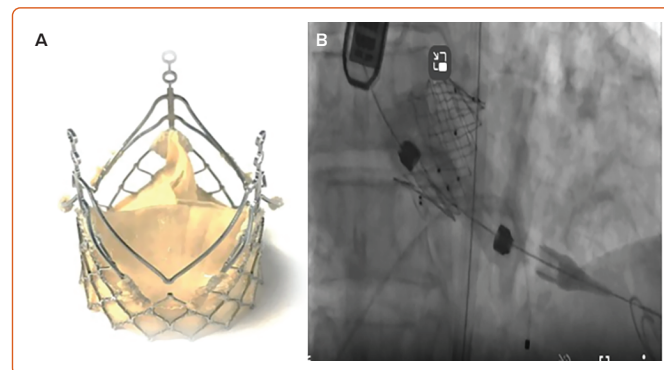
The Cusper device consists of a nitinol clip (3.4 × 16 mm) and a pericardial sac (6 mm in diameter) fixed to the clip (*Figure 4 and Table 1*). The implant is secured within a specialised delivery catheter equipped with proximal and distal fixation mechanisms. The system is intended for percutaneous implantation using a 16 Fr sheath and is designed to fill the effective regurgitant orifice of the aortic valve.⁵⁸

Figure 4: The Cusper Device



A: Valve. B: Implantation. C: In animal. Reproduced with permission from Cuspa Foundation.

Figure 5: Laguna Devices



A: The ALPHA valve. B: The ZETA valve. Reproduced with permission from Laguna Tech.

The experimental protocol was approved by the animal study committee of the Assaf Harofeh Medical Center and the Lahav Contract Research Organization, both in Israel. The proof of concept was evaluated using various methods, including *ex vivo* pig heart experiments. Successful device implantation was achieved in seven of nine animals. Two cases experienced complications, including embolisation and perforation, which were attributed to the learning curve associated with the novel implantation procedure. AR was reassessed in the pigs using Doppler echocardiography (*Figure 2*) after implantation of the Cusper device and only trivial AR was detected.⁵⁸ Long-term preclinical studies, including animal and human cadaveric investigations, are currently in progress.

ZETA and ALPHA Devices

Laguna Tech has developed two TAVR devices for the treatment of aortic insufficiency. The ZETA is a balloon-expandable valve, featuring six expanding arms and a low-profile, covered delivery system (*Figure 5 and Table 1*). A single-centre study in Chile successfully treated five patients with the ZETA valve, achieving a 100% device success rate.⁵⁹

The ALPHA system is a novel, single-piece, self-expanding THV with a streamlined design and a low-profile valve and delivery system (*Figure 5*). Featuring six support arms, the system facilitates simpler and more accurate positioning within the aortic annulus and cusps. In the ALPHA Aortic Valve study, two patients underwent successful implantations,

demonstrating immediate and sustained resolution of AR at 30-day follow-up.⁶⁰

Conclusion

Over the past decade, significant progress has been made in TAVR for the treatment of AR. Early-generation devices were associated with high mortality rates. However, subsequent generations of off-label and dedicated devices have shown improved performance, culminating in the

CE Mark approval of dedicated devices such as the Trilogy system and J-Valve.

Given the diverse aetiologies and anatomical variations of AR, such as active endocarditis, aortic dilatations and bicuspid aortic valve (which were excluded from many of the earlier studies), it is anticipated that multiple devices will be necessary to effectively address the spectrum of AR pathologies. □

- Singh JP, Evans JC, Levy D, et al. Prevalence and clinical determinants of mitral, tricuspid, and aortic regurgitation (the Framingham Heart Study). *Am J Cardiol* 1999;83:897–902. [https://doi.org/10.1016/s0002-9149\(98\)01064-9](https://doi.org/10.1016/s0002-9149(98)01064-9); PMID: 10190406.
- Bekeredjian R, Grayburn PA. Valvular heart disease: aortic regurgitation. *Circulation* 2005;112:125–34. <https://doi.org/10.1161/CIRCULATIONAHA.104.488825>; PMID: 15998697.
- Vahanian A, Beyersdorf F, Praz F, et al. ESC/EACTS guidelines for the management of valvular heart disease. *EuroIntervention* 2021;17:e1126–96. <https://doi.org/10.4244/EIJ-E-21-00009>; PMID: 34931612.
- Ranard LS, Vahl TP. Current and future TAVR devices for aortic insufficiency. *Cardiac Interventions Today* 2024;18:2.
- Dujardin KS, Enriquez-Sarano M, Schaff HV, et al. Mortality and morbidity of aortic regurgitation in clinical practice. A long-term follow-up study. *Circulation* 1999;99:1851–7. <https://doi.org/10.1161/01.CIR.99.14.1851>; PMID: 10199882.
- De Backer O, Pilgrim T, Simonato M, et al. Usefulness of transcatheter aortic valve implantation for treatment of pure native aortic valve regurgitation. *Am J Cardiol* 2018;122:1028–35. <https://doi.org/10.1016/j.amjcard.2018.05.044>; PMID: 30072124.
- Franzone A, Piccolo R, Siontis GCM, et al. Transcatheter aortic valve replacement for the treatment of pure native aortic valve regurgitation: a systematic review. *JACC Cardiovasc Interv* 2016;9:2308–17. <https://doi.org/10.1016/j.jcin.2016.08.049>; PMID: 28026742.
- Roy DA, Schaefer U, Guevra V, et al. Transcatheter aortic valve implantation for pure severe native aortic valve regurgitation. *J Am Coll Cardiol* 2013;61:1577–84. <https://doi.org/10.1016/j.jacc.2013.01.018>; PMID: 23433565.
- Testa L, Latib A, Rossi ML, et al. CoreValve implantation for severe aortic regurgitation: a multicentre registry. *EuroIntervention* 2014;10:739–45. <https://doi.org/10.4244/EIJV10I6A127>; PMID: 25330506.
- Rawasia WF, Khan MS, Usman MS, et al. Safety and efficacy of transcatheter aortic valve replacement for native aortic valve regurgitation: a systematic review and meta-analysis. *Catheter Cardiovasc Interv* 2019;93:345–53. <https://doi.org/10.1002/CCD.27840>; PMID: 30269437.
- Sawaya FJ, Deutsch MA, Seiffert M, et al. Safety and efficacy of transcatheter aortic valve replacement in the treatment of pure aortic regurgitation in native valves and failing surgical bioprostheses: results from an international registry study. *JACC Cardiovasc Interv* 2017;10:1048–56. <https://doi.org/10.1016/j.jcin.2017.03.004>; PMID: 28521923.
- Yoon S-H, Schmidt T, Bleiziffer S, et al. Transcatheter aortic valve replacement in pure native aortic valve regurgitation. *J Am Coll Cardiol* 2017;70:2752–63. <https://doi.org/10.1016/j.jacc.2017.10.006>; PMID: 29191323.
- Maeno Y, Yoon S-H, Abramowitz Y, et al. Effect of ascending aortic dimension on acute procedural success following self-expanding transcatheter aortic valve replacement: a multicenter retrospective analysis. *Int J Cardiol* 2017;244:100–5. <https://doi.org/10.1016/j.ijcard.2017.05.120>; PMID: 28622944.
- Takagi H, Hari Y, Kawai N, et al. Meta-analysis and meta-regression of transcatheter aortic valve implantation for pure native aortic regurgitation. *Heart Lung Circ* 2020;29:729–41. <https://doi.org/10.1016/j.hlc.2019.04.012>; PMID: 31133516.
- Bekeredjian R, Grayburn PA. Valvular heart disease: aortic regurgitation. *Circulation* 2005;112:125–34. <https://doi.org/10.1161/CIRCULATIONAHA.104.488825>; PMID: 15998697.
- Franzone A, Piccolo R, Siontis GCM, et al. Transcatheter aortic valve replacement for the treatment of pure native aortic valve regurgitation: a systematic review. *JACC Cardiovasc Interv* 2016;9:2308–17. <https://doi.org/10.1016/j.jcin.2016.08.049>; PMID: 28026742.
- Liu R, Fu Z, Jiang Z, et al. Transcatheter aortic valve replacement for aortic regurgitation: a systematic review and meta-analysis. *ESC Heart Fail* 2024;11:3488–500. <https://doi.org/10.1002/ehf2.14832>; PMID: 38749505.
- Bax JJ, Delgado V, Hahn RT, et al. Transcatheter aortic valve replacement: role of multimodality imaging in common and complex clinical scenarios. *JACC Cardiovasc Imaging* 2020;13:124–39. <https://doi.org/10.1016/j.jcmg.2018.10.037>; PMID: 31103575.
- Noble S, Mauler-Wittwer S. TAVR as an alternative to SAVR for pure native aortic regurgitation. *Can J Cardiol* 2024;40:316–25. <https://doi.org/10.1016/j.cjca.2023.11.023>; PMID: 38016541.
- Delgado V, Peláez ED. Severe aortic regurgitation: the limits of TAVI. *EuroIntervention* 2024;20:e1051–2. <https://doi.org/10.4244/EIJ-E-24-00045>; PMID: 39229834.
- Urena M, Himbert D, Ohlmann P, et al. Transcatheter aortic valve replacement to treat pure aortic regurgitation on noncalcified native valves. *J Am Coll Cardiol* 2016;68:1705–6. <https://doi.org/10.1016/j.jacc.2016.07.746>; PMID: 27712786.
- Liu R, Fu Z, Yao J, et al. Transcatheter aortic valve replacement for aortic regurgitation – a review. *Cardiovasc Innov Appl* 2023;8. <https://doi.org/10.15212/CVIA.2023.0033>.
- Poletti E, De Backer O, Scotti A, et al. Transcatheter aortic valve replacement for pure native aortic valve regurgitation: the Pantheon international project. *JACC Cardiovasc Interv* 2023;16:1974–85. <https://doi.org/10.1016/j.jcin.2023.07.026>; PMID: 37648345.
- Bruschi G, De Marco F, Martinelli L, et al. CoreValve® transcatheter self-expandable aortic bioprosthesis. *Expert Rev Med Devices* 2013;10:15–26. <https://doi.org/10.1586/ERD.12.64>; PMID: 23278219.
- Samimi S, Hatab T, Kharsa C, et al. Meta-analysis of dedicated vs off-label transcatheter devices for native aortic regurgitation. *JACC Cardiovasc Interv* 2025;18:44–57. <https://doi.org/10.1016/j.jcin.2024.08.042>; PMID: 39570231.
- Sánchez-Luna JP, Martín P, Dager AE, et al. Clinical outcomes of TAVI with the Myval balloon-expandable valve for non-calcified aortic regurgitation. *EuroIntervention*, 2023;19:580–5. <https://doi.org/10.4244/EIJ-D-23-00344>; PMID: 37565470.
- Medtronic. Evolut R System. EVOLUT R SYSTEM Transcatheter Aortic Valve Replacement (TAVI). 2024. <https://europe.medtronic.com/xd-en/healthcare-professionals/products/cardiovascular/transcatheter-aortic-heart-valves/evolut-r.html> (accessed 29 October 2025).
- Frerker C, Schewel J, Schewel D, et al. Expansion of the indication of transcatheter aortic valve implantation – feasibility and outcome in ‘off-label’ patients compared with ‘on-label’ patients. *J Invasive Cardiol* 2015;27:229–36. PMID: 25929299.
- Sinning JM, Werner N, Nickenig G, Grube E. Medtronic CoreValve Evolut valve. *EuroIntervention* 2012;8:q94–6. <https://doi.org/10.4244/EIJV8SQA17>; PMID: 22995121.
- Edwards. Instructions for Use/Operator’s Manual. 2025. <http://THVIFU.edwards.com> (accessed 20 January 2025).
- Delhomme C, Urena M, Zouaghi O, et al. Transcatheter aortic valve implantation using the SAPIEN 3 valve to treat aortic regurgitation: the French multicentre S3AR study. *Arch Cardiovasc Dis* 2023;116:98–105. <https://doi.org/10.1016/j.acvd.2022.12.003>; PMID: 36707263.
- Sharma SK, Rao RS, Chandra P, et al. First-in-human evaluation of a novel balloon-expandable transcatheter heart valve in patients with severe symptomatic native aortic stenosis: the MyVal-1 study. *EuroIntervention* 2020;16:421–9. <https://doi.org/10.4244/EIJ-D-19-00413>; PMID: 31566572.
- Kilic T, Coskun S, Mirzamidinov D, et al. Myval transcatheter heart valve: the future of transcatheter valve replacement and significance in current timeline. *J Clin Med* 2024;13:6857. <https://doi.org/10.3390/JCM13226857>; PMID: 39598000.
- Jose J, Mandalay A, Cholenahally MN, et al. Safety and effectiveness of the novel Myval Octacor transcatheter heart valve in severe, symptomatic aortic valve stenosis – a real-world Indian experience (the OCTACOR India Study). *Cardiovasc Revasc Med* 2024;63:1–7. <https://doi.org/10.1016/j.carrev.2024.01.016>; PMID: 38423848.
- Vila-Olives R, Oristrell G, Rello P, Fernández-Hidalgo N. Transcatheter aortic valve replacement for acute aortic regurgitation due to *Staphylococcus aureus* infective endocarditis complicated with a perivalvular abscess: a case report. *Eur Heart J Case Rep* 2023;7:ytad166. <https://doi.org/10.1093/EHJCR/YTAD166>; PMID: 37090761.
- Takagi H, Hari Y, Kawai N, Ando T. Meta-analysis and meta-regression of transcatheter aortic valve implantation for pure native aortic regurgitation. *Heart Lung Circ* 2020;29:729–41. <https://doi.org/10.1016/j.hlc.2019.04.012>; PMID: 31133516.
- Sánchez-Luna JP, Martín P, Dager AE, et al. Clinical outcomes of TAVI with the Myval balloon-expandable valve for non-calcified aortic regurgitation. *EuroIntervention* 2023;19:580–5. <https://doi.org/10.4244/EIJ-D-23-00344>; PMID: 37565470.
- Wienemann H, Elzomor H, Kuhn E, et al. Transcatheter aortic valve implantation of a novel system for severe pure native aortic regurgitation in a patient with an ascending aorta aneurysm. *EuroIntervention* 2023;18:1442–3. <https://doi.org/10.4244/EIJ-D-22-00747>; PMID: 36416185.
- Hensley M, Murdoch DJ, Sathananthan J, et al. First-in-human experience of a new-generation transfemoral transcatheter aortic valve for the treatment of severe aortic regurgitation: the J-Valve transfemoral system. *EuroIntervention* 2019;14:e1553–5. <https://doi.org/10.4244/EIJ-D-18-00935>; PMID: 30451688.
- Falk V. Transcatheter aortic valve replacement indications should not be expanded to lower risk and younger patients. *Circulation* 2014;130:2332–42. <https://doi.org/10.1161/circulationaha.114.008145>; PMID: 25539521.
- Roy D, Sharma R, Brecker SJD. Native aortic valve regurgitation: transcatheter therapeutic options. *EuroIntervention* 2013;9:S55–62. <https://doi.org/10.4244/EIJV9S5A11>; PMID: 24025959.
- Berman E, Abu-Much A, Reisman M, et al. Contemporary review of the methods for rapid ventricular pacing during transcatheter aortic valve replacement. *Struct Heart* 2025;9:100306. <https://doi.org/10.1016/j.shj.2024.100306>; PMID: 40124080.
- Lee GS, Tang G, Zaid S, Tam DY. The current state of retro transcatheter aortic valve replacement (TAVR) and limitations: why TAVR explant is important as the valve reintervention strategy. *Ann Cardiothorac Surg* 2025;14:98–111. <https://doi.org/10.21037/ACS-2024-ETAVR-0149>; PMID: 40270850.
- Das R, Puri R. Transcatheter treatment of bicuspid aortic valve disease: imaging and interventional considerations. *Front Cardiovasc Med* 2018;5:91. <https://doi.org/10.3389/fcvm.2018.00091>; PMID: 30073170.
- Al Ahmad J, Danson E. Transcatheter aortic valve implantation for severe chronic aortic regurgitation. *J Clin Med* 2024;13:2997. <https://doi.org/10.3390/JCM13102997>; PMID: 38792538.
- Santangelo G, Ielasi A, Pellicano M, et al. An update on new generation transcatheter aortic valves and delivery systems. *J Clin Med* 2022;11:499. <https://doi.org/10.3390/JCM11030499>; PMID: 35159952.
- Baumbach A, Patel KP, Kennon S, et al. A heart valve dedicated for aortic regurgitation: review of technology and early clinical experience with the transfemoral Trilogy system. *Catheter Cardiovasc Interv* 2023;102:766–71. <https://doi.org/10.1002/CCD.30795>; PMID: 37560819.
- Ingléssis-Azuaje I. Transcatheter aortic valve replacement for pure aortic insufficiency: conquering the next frontier? *JACC Case Rep* 2021;3:650–2. <https://doi.org/10.1016/j.jaccas.2021.03.004>; PMID: 34317596.
- Vahanian A, Beyersdorf F, Praz F, et al. 2021 ESC/EACTS guidelines for the management of valvular heart disease. *Eur Heart J* 2021;43:561–632. <https://doi.org/10.1093/EURHEARTJ/EHAB395>; PMID: 34453165.
- Seiffert M, Bader R, Kappert U, et al. Initial German experience with transapical implantation of a second-generation transcatheter heart valve for the treatment of aortic regurgitation. *JACC Cardiovasc Interv* 2014;7:1168–74. <https://doi.org/10.1016/j.jcin.2014.05.014>; PMID: 25129672.
- Silaschi M, Conradi L, Wendler O, et al. The Jupiter registry: one-year outcomes of transapical aortic valve implantation

- using a second generation transcatheter heart valve for aortic regurgitation. *Catheter Cardiovasc Interv* 2018;91:1345–51. <https://doi.org/10.1002/CCD.27370>; PMID: 29171730.
52. Adam M, Tamm A, Wienemann H, et al. Transcatheter aortic valve replacement for isolated aortic regurgitation using a new self-expanding TAVR system. *JACC Cardiovasc Interv* 2023;16:1965–73. <https://doi.org/10.1016/j.jcin.2023.07.038>; PMID: 37648344.
 53. Vahl TP, Thourani VH, Makkar RR, et al. Transcatheter aortic valve implantation in patients with high-risk symptomatic native aortic regurgitation (ALIGN-AR): a prospective, multicentre, single-arm study. *Lancet* 2024;403:1451–9. [https://doi.org/10.1016/S0140-6736\(23\)02806-4](https://doi.org/10.1016/S0140-6736(23)02806-4); PMID: 38552656.
 54. Thourani VH, Suri RM, Gunter RL, et al. Contemporary real-world outcomes of surgical aortic valve replacement in 141,905 low-risk, intermediate-risk, and high-risk patients. *Ann Thorac Surg* 2015;99:55–61. <https://doi.org/10.1016/j.athoracsur.2014.06.050>; PMID: 25442986.
 55. Liu H, Yang Y, Wang W, et al. Transapical transcatheter aortic valve replacement for aortic regurgitation with a second-generation heart valve. *J Thorac Cardiovasc Surg* 2018;156:106–16. <https://doi.org/10.1016/j.jtcvs.2017.12.150>; PMID: 29525255.
 56. Garcia S, Ye J, Webb J, et al. Transcatheter treatment of native aortic valve regurgitation: the North American experience with a novel device. *JACC Cardiovasc Interv* 2023;16:1953–60. <https://doi.org/10.1016/j.jcin.2023.05.018>; PMID: 37212431.
 57. Samimi S, Hatab T, Kharsa C, et al. Meta-analysis of dedicated vs off-label transcatheter devices for native aortic regurgitation. *JACC Cardiovasc Interv* 2025;18:44–57. <https://doi.org/10.1016/j.jcin.2024.08.042>; PMID: 39570231.
 58. Feld Y, Yakobi D, Hazan S, Weigler A. Transcatheter aortic valve repair for aortic regurgitation with the Cusper device. *EuroIntervention* 2022;18:e179–80. <https://doi.org/10.4244/EIJ-D-22-00074>; PMID: 35592950.
 59. Diagnostic and Interventional Cardiology. Laguna Tech USA announces site record number of transcatheter heart valves implanted at single center on same day in first-in-human clinical trial. 2024. <https://www.dicardiology.com/content/laguna-tech-usa-announces-site-record-number-transcatheter-heart-valves-implanted-single> (accessed 21 January 2025).
 60. Clinical Accelerator. Laguna Tech USA announces newly designed heart valves with advanced engineering successfully implanted in first-in-human clinical trial. 2023. <https://clinicalaccelerator.com/2023/11/22/laguna-tech-usa-announces-newly-designed-heart-valves-with-advanced-engineering-successfully-implanted-in-first-in-human-clinical-trial/> (accessed 21 January 2025).