

Original Research Article

Our initial experience of three versus two rows circular stapler devices for stapled hemorrhoidopexy: a single institution review of 224 cases

Paritosh Gupta, Dhruv N. Kundra*, Amanpriya Khanna, Akanksha Aggarwal, Kanu Kapoor

Department of Minimal Access and Metabolic Surgery, Artemis Hospital, Gurugram, Haryana, India

Received: 10 January 2020

Revised: 23 January 2020

Accepted: 29 January 2020

*Correspondence:

Dr. Dhruv N. Kundra,

E-mail: drdhruvkundra@gmail.com

Copyright: © the author(s), publisher and licensee Medip Academy. This is an open-access article distributed under the terms of the Creative Commons Attribution Non-Commercial License, which permits unrestricted non-commercial use, distribution, and reproduction in any medium, provided the original work is properly cited.

ABSTRACT

Background: Stapled haemorrhoidopexy is a non-excisional approach for haemorrhoids as opposed to conventional open Milligan-Morgan and Ferguson closed haemorrhoidectomy techniques. It repositions the prolapsed haemorrhoid tissue and also causes vascular interruption to the haemorrhoids. This causes faster recovery and lesser post-operative pain.

Methods: In authors institute, stapled haemorrhoidopexy was being carried out using two rows proximate PPH circular haemorrhoidal stapler. In February 2018, MIRUS three rows circular stapler was introduced. This is a retrospective observational study carried out at Artemis Hospital, Gurgaon, India. Authors studied records and operative notes of all patients who underwent stapled haemorrhoidopexy between February 2018 and September 2019 and compared key parameters.

Results: A total of 224 patients underwent stapled haemorrhoidopexy between February 2018 and September 2019. 116 using MIRUS three rows circular stapler and 108 using two rows proximate PPH circular haemorrhoidal stapler. Most of the studied parameters were comparable with only significant statistical difference seen in higher use of haemostatic sutures in two rows stapler group compared to three rows stapler group. Haemostatic sutures were needed in three row stapler group for 27 patients and in two rows stapler group for 39 patients.

Conclusions: Author's initial experience shows slightly better haemostasis with three rows stapled haemorrhoidopexy with no significant difference in other parameters.

Keywords: Haemorrhoid, Haemostasis, Stapled haemorrhoidopexy

INTRODUCTION

Haemorrhoidectomy is one of the most commonly performed anorectal operations.¹ Conventionally grade three and four haemorrhoids have been operated with open excisional techniques which have been associated with significant post-operative pain.²

Stapled haemorrhoidopexy was introduced in the year 1998 by Longo.³ It repositions the prolapsed haemorrhoids tissue and also causes an interruption of the vascular supply to the haemorrhoids cushions by circular

resection of the inner layers of rectum above the dentate line.⁴

It has shown faster recovery, lesser post-operative pain and an early return to normal activities.^{5,6} Over years it has gained popularity over traditional open procedures due to its minimally invasive nature with no external scars and lesser short-term pain.⁷ In this institute, stapled haemorrhoidopexy was being carried out using two rows proximate PPH circular hemorrhoidal stapler. In February 2018 MIRUS three rows circular stapler was made available for use.

In this study we observed parameters like operative time, need for hemostatic sutures, need for additional post-operative analgesics, post-operative bleeding requiring intervention, hospital stay and re-admission between the two groups of patients.

METHODS

This is a retrospective observational cohort study carried out at Artemis Hospital, Gurgaon, India. Authors studied records and operative notes of all patients who underwent stapled haemorrhoidopexy between February 2018 and September 2019. Parameters studied were operative time, need for hemostatic sutures, need for additional post-operative analgesics, post-operative bleeding requiring intervention, hospital stay and re-admission.

The choice of stapling device for procedure was decided by the operating surgeon. Pre-operative consent was taken from all patients.

Inclusion criteria

All patients who underwent stapled haemorrhoidopexy between February 2018 and September 2019 were included in the study.

Exclusion criteria

Patients who had undergone haemorrhoidectomy earlier and patients who underwent additional perianal procedures like fistulectomy, lateral internal sphincterotomy etc. were excluded.

Operative notes were studied for operative time and need for hemostatic sutures. Patient records were studied for need of additional analgesics beyond the routine practice of giving IV analgesics on the operative day and shifting to oral analgesics from first post-operative day. Any re-operation during the same admission for post-operative bleeding or any re-admission for same was also noted.

Hospital stay was counted from the day of surgery. Patients were usually discharged on first post-operative day; any additional stay was noted.

After compiling the data, Chi square test was applied to calculate p value and find out statistically significant difference in the studied parameters between two and three rows stapler groups.

Procedure

All patients were administered anaesthesia (spinal or general anaesthesia) prior to surgery. Patients were placed in extended lithotomy position. Digital and proctoscopic examination was done using lignocaine jelly. Anal port was placed and fixed using silk sutures. Stapler gun was used as per surgeon's preference (Figure 1a, 1b). A purse string suture was placed 3 cms above

dentate line. Anvil of stapler gun was inserted beyond purse string suture and suture was tightened (Figure 2). Stapler was tightened up to the indicated mark on gun and fired. Stapler was opened and removed along with the haemorrhoidal "Doughnut". Stapler line was examined for hemostasis (Figure 3a and b) and any hemostatic sutures if required were taken. Doughnut was examined for completeness (Figure 4).

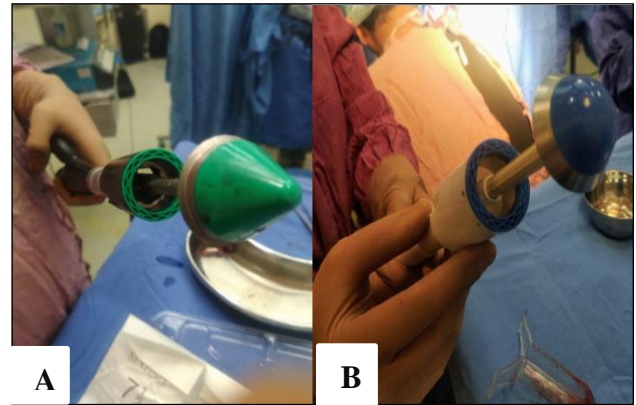


Figure 1: (A) Two row stapler gun and (B) three row stapler gun.

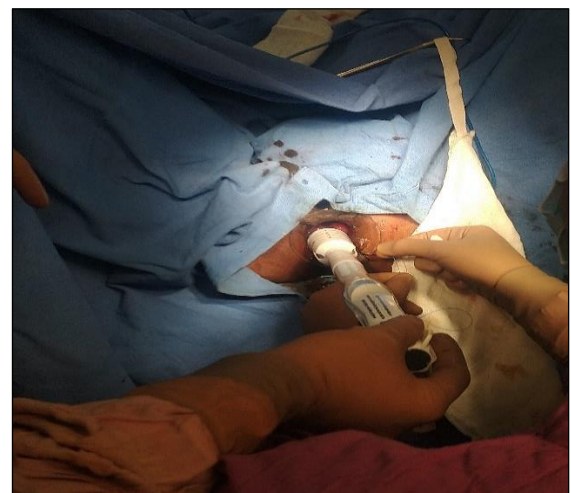

Figure 2: Purse string suture tightened after inserting the anvil.

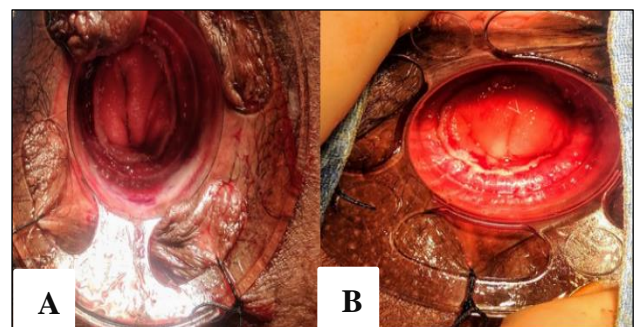


Figure 3: (A) Three row staple line and (B) two row staple line.

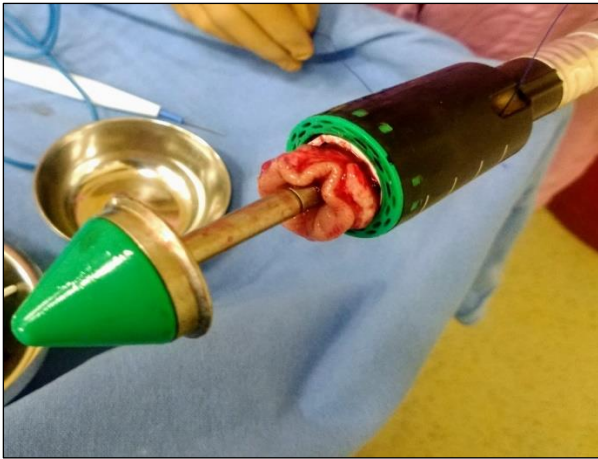

Figure 4: Haemorrhoidal doughnut.

An anal pack was placed, and dressing was done.

RESULTS

A total of 224 patients underwent stapled haemorrhoidopexy between February 2018 and September 2019. 116 using MIRUS three rows circular stapler and 108 using two rows proximate PPH circular haemorrhoidal stapler. In three rows stapler group there were 68 male and 48 female patients, mean age of patients was 48.3 years. In two rows stapler group there were 71 male and 37 female patients, mean age of patients was 49.2 years. Mean operating time for three row stapler group was 48 mins and two rows stapler group were 46 mins. Use of hemostatic sutures in three row stapler group was needed for 27 patients and in two rows stapler group for 39 patients.

Table 1: Statistical analysis of various parameters.

Parameter	Group 1 (three row)	Group 2 (two row)	P value	Significance
Patients (n)	116	108		
Mean operative time (mins)	48	46	0.78	No
Haemostatic sutures	27	39	0.036	Yes
Additional analgesia	33	25	0.367	No
Re surgery for bleeding	0	2	0.142	No
Re admission for bleeding	0	0	1	No
Post-operative stay (days)	1.17	1.19	0.541	No
Age (years)	48.3	49.2	0.498	No
Gender (male)	68	71	0.273	No
Female	48	37	0.327	No

Additional analgesia was required in 33 patients in three row stapler group and in 25 patients in two rows stapler group. Two patients required re-surgery for bleeding in two rows stapler group and none in three rows stapler group. Mean post-operative hospital stay for three row stapler group was 1.17 days and two rows stapler group were 1.19 days. No patient in either group required re-admission for any reason. On applying Chi square test p values were found to be significant in use of hemostatic sutures. There was no major difference in duration of hospital stay, need for additional analgesia, or post-operative pain (Table 1).

DISCUSSION

Haemorrhoidal disease is ranked first amongst diseases of the rectum and large intestine, and the estimated worldwide prevalence ranges from 2.9% to 27.9%, of which more than 4% are symptomatic.⁸ Approximately, one third of these patients seek physicians for advice. Age distribution demonstrates a Gaussian distribution with a peak incidence between 45 and 65 years.⁹ Around half of the population has some degree of affection by the age of 50 years.¹⁰ Men are more frequently affected than women.¹¹ Surgical management of haemorrhoids has progressed tremendously

from complex ligation procedures in the past to simpler techniques today that allow the patient to return to normal activities in a short period.

The development of the stapler haemorrhoidopexy technique was the first attempt to deal with the disease of haemorrhoids without recourse to excision or ligation of the haemorrhoidal masses.¹² Longo developed the device in 1998 and developed a technique that, using a circular stapler, reduced haemorrhoidal prolapse. This is possible by removing a transverse band of prolapsed rectal mucosa between the rectal ampulla and anal canal. Furthermore, this technique restores the anal mucosa and the haemorrhoidal cushions within the anal canal, thus improving continence.¹³ This not only shortens the prolapsing mucosa, but it also disrupts the branches of the haemorrhoidal arteries which feed the anal cushions.

Use of circular stapler haemorrhoidopexy results in same or improved safety and efficacy outcomes as those of conventional methods. Sutherland et al in 2002, reviewed seven randomized controlled trials which compared stapled with conventional haemorrhoidectomy. There was a reasonably clear evidence in favour of the stapled procedure for bleeding at 2 weeks and length of hospital

stay.¹⁴ Other results in favour of stapled procedure related to pain, bleeding, anal discharge, wound healing, tenderness at per rectal examination, incontinence scores, earlier return of bowel function, analgesic requirement and resumption of normal activities.

Overall early and late complications of stapled haemorrhoidopexy have been said to be similar to those seen with conventional haemorrhoidectomy, with some articles even demonstrating lower complication rate in stapled technique.¹⁵ In this institute stapled haemorrhoidopexy was being carried out using two rows proximate PPH circular haemorrhoidal stapler. In February 2018 MIRUS three rows circular stapler was made available for use. Initial results in this study have shown three rows stapled haemorrhoidopexy group to have better staple line hemostasis as evidenced by lesser need for intra or post-operative intervention for bleeding. Other parameters were comparable. Authors could not find similar study comparing these two devices.

However, in a study of 340 cases comparing three and two row linear stapled ileo-colic anastomosis it was found that anastomoses with triple-row staples tended to have a lower morbidity rate.¹⁶

CONCLUSION

Author's initial experience shows slightly better hemostasis with three rows stapled haemorrhoidopexy but larger randomized controlled trials are needed to conclusively establish the benefits and evaluate long term outcomes of these devices.

Funding: No funding sources

Conflict of interest: None declared

Ethical approval: Not required

REFERENCES

1. Sayfan J, Becker A, Koltun L. Sutureless closed hemorrhoidectomy: a new technique. *Ann Surg*. 2001;234(1):21-4.
2. Gerbershagen HJ, Aduckathil S, Van Wijck AJ, Peelen LM, Kalkman CJ, Meissner W. Pain intensity on the first day after surgery: a prospective cohort study comparing 179 surgical procedures. *Anesthesiology*. 2013;118:934-44.
3. Longo A. Treatment of hemorrhoidal disease by reduction of mucosa and hemorrhoidal prolapse with a circular suturing device; 6th World Congress of Endoscopic Surgery; Rome, Italy: Bologna: Monduzzi; 1998: 777-784.
4. Araujo SE, Horcel LA, Seid VE, Bertoncini AB, Klajner S. Long term results after Stapled Hemorrhoidopexy alone and complemented by excisional Hemorrhoidectomy: A Retrospective Cohort Study. *Arq Bras Cir Dig*. 2016;29(3):159-63.
5. Systematic review on the procedure for prolapse and hemorrhoids (stapled hemorrhoidopexy). Tjandra JJ, Chan MK. *Dis Colon Rectum*. 2007;50(6):878-92.
6. Pavlidis T, Papaziogas B, Souparis A, Patsas A, Koutelidakis I, Papaziogas T. Modern stapled Longo procedure vs. conventional Milligan-Morgan hemorrhoidectomy: a randomized controlled trial. *Int J Colorectal Dis*. 2002;17(1):50-3.
7. Watson AJ, Bruhn H, MacLeod K, McDonald A, McPherson G, Kilonzo M, et al. A pragmatic, multicentre, randomised controlled trial comparing stapled haemorrhoidopexy to traditional excisional surgery for haemorrhoidal disease (eTHoS): study protocol for a randomised controlled trial. *Trials*. 2014;15(1):439.
8. Johanson JF, Sonnenberg A. The prevalence of hemorrhoids and chronic constipation. An epidemiologic study. *Gastroenterol*. 1990;98(2):380-6.
9. Rogozina VA. *Eksp Klin Gastroenterol Exp Clin Gastroenterol*. 2002;4:93-6.
10. Cohen Z. Symposium on outpatient anorectal procedures. Alternatives to surgical hemorrhoidectomy. *Can J Surg J Can Chir*. 1985;28(3):230-1.
11. Bartolo DC. Surgery of the anus, rectum and colon. Vols 1 and 2. MRB Keighley and NS Williams. 282x 205 mm. Pp. 2448. Illustrated. 1993. London: WB Saunders. £ 280. *British J Surg*. 1994;81(7):1085.
12. Corman ML, Gravié J-F, Hager T, Loudon MA, Mascagni D, Nyström P-O, et al. Stapled haemorrhoidopexy: a consensus position paper by an international working party - indications, contraindications and technique. *Colorectal Dis Off J Assoc Coloproctol G B Irel*. 2003;5(4):304-10.
13. Lomanto D, Katara AN. Stapled Haemorrhoidopexy for Prolapsed Haemorrhoids: Short- and Long-term Experience. *Asian J Surg*. 2007;30(1):29-33.
14. Sutherland LM, Burchard AK, Matsuda K, Sweeney JL, Bokey EL, Childs PA, et al. A systematic review of stapled hemorrhoidectomy. - PubMed - NCBI. Available at: <https://www.ncbi.nlm.nih.gov/pubmed/12470107?dopt=Abstract>. Accessed 11 December 2019.
15. Touzin E, Hegge S, McKinley C. Early experience of stapled hemorrhoidectomy in a community hospital setting. *Can J Surg*. 2006;49(5):316-20.
16. Foo CC, Chiu AH, Yip J, Law WL. Does advancement in stapling technology with triple-row and enhanced staple configurations confer additional safety? A matched comparison of 340 stapled ileocolic anastomoses. *Surgical endoscopy*. 2018;32(7):3122-30.

Cite this article as: Gupta P, Kundra DN, Khanna A, Aggarwal A, Kapoor K. Our initial experience of three versus two rows circular stapler devices for stapled hemorrhoidopexy: a single institution review of 224 cases. *Int Surg J* 2020;7:685-8.