



2024

## Early Outcomes of Transcatheter Aortic Valve Implantation with Next-Generation Balloon-Expandable Myval Transcatheter Heart Valve: Single-Center Experience from Iraq

Follow this and additional works at: <https://www.j-saudi-heart.com/jsha>



Part of the [Cardiology Commons](#)



This work is licensed under a [Creative Commons Attribution-Noncommercial-No Derivative Works 4.0 License](#).

### Recommended Citation

Amber, Khalid Ibrahim and Majeed, Ammar Jabbar (2024) "Early Outcomes of Transcatheter Aortic Valve Implantation with Next-Generation Balloon-Expandable Myval Transcatheter Heart Valve: Single-Center Experience from Iraq," *Journal of the Saudi Heart Association*: Vol. 36 : Iss. 1 , Article 9.  
Available at: <https://doi.org/10.37616/2212-5043.1370>

This Original Article is brought to you for free and open access by Journal of the Saudi Heart Association. It has been accepted for inclusion in Journal of the Saudi Heart Association by an authorized editor of Journal of the Saudi Heart Association.

# Early Outcomes of Transcatheter Aortic Valve Implantation With Next-generation Balloon-expandable Myval Transcatheter Heart Valve: Single-center Experience From Iraq

Khalid Amber<sup>\*</sup>, Ammar J. Majeed

Al-Najaf Centre for Cardiac Surgery and Transcatheter Therapy, Kufa, Iraq

## Abstract

**Objectives:** Transcatheter aortic valve implantation (TAVI) is a minimally invasive percutaneous procedure for the treatment of elderly patients with symptomatic severe aortic stenosis. The study aimed to determine immediate (in-hospital) and short-term (30-day) outcomes of TAVI with next-generation balloon-expandable Myval transcatheter heart valve (THV) at a single-centre in Iraq.

**Methods:** During January 2019 to January 2024, a total of 100 symptomatic severe aortic stenosis patients who underwent TAVI using Myval THV at Al-Najaf Cardiac Center, Iraq were enrolled. The procedure was done under local anesthesia and conscious sedation via transfemoral approach, using balloon-expandable Myval THV. All patients were followed-up at post-procedure, during hospitalization and thereafter periodically for procedural and clinical outcomes and complications.

**Results:** The mean age of these patients was  $73.8 \pm 6.5$  years and there were equal proportion of male and female patients. Immediate post-procedure and short-term mortality was 1%, while vascular complications, moderate para-valvular leak and overall conduction abnormalities were 11%, 4% and 21%, respectively at 30-day follow-up. Only six patients (6%) required a new permanent pacemaker. Post-procedural mean pressure gradient was  $5.44 \pm 2.38$  mmHg. None of the treated patients experienced coronary artery occlusion. Cerebrovascular complication (transient and non-disabling) was noted in one patient.

**Conclusion:** In patients with native symptomatic severe aortic stenosis, TAVI using novel, next-generation, balloon-expandable Myval THV offers a safe and reliable treatment option with good procedural success and survival rates and fewer complications.

**Keywords:** Aortic stenosis, Transcatheter aortic valve implantation, Balloon-expandable THV, Minimally invasive percutaneous intervention

## 1. Introduction

Aortic valve stenosis (AS) represents the most common valvular heart disease in Western countries [1]. It is characterized by progressive thickening, fibrosis, and calcification of the valve, leading to restriction of leaflets' movement and obstruction. It affects about 2% of the population

over the age of 65, 3% over 75 and 4% over 85 years of age, and with an ageing population, the incidence is projected to increase [2–4]. In congenital AS, there is narrowing of the aortic orifice in adulthood [5]. Risk factors for degenerative calcific AS include advanced age, hypertension, hypercholesterolemia, diabetes mellitus, and smoking [6]. In patients with unrelieved aortic valve obstruction, the onset of

Received 4 March 2024; revised 14 April 2024; accepted 17 April 2024.  
Available online 12 May 2024

\* Corresponding author at: Al-Najaf Centre for Cardiac Surgery and Transcatheter Therapy Kufa, Najaf Governorate, Iraq.  
E-mail address: [Khalidamber4@gmail.com](mailto:Khalidamber4@gmail.com) (K. Amber).



symptoms predicts a poor outcome with medical therapy [7,8].

The transcatheter aortic valve implantation (TAVI) procedure has become the standard treatment for high surgical-risk patients and even for intermediate and low surgical-risk patients [9,10]. The major complications with TAVI include cerebrovascular events, vascular complications, coronary obstruction, myocardial infarction, valve regurgitation, conduction disturbances and acute kidney injury (AKI) [7]. With advances in medical equipment and heart team, improvements in procedural techniques together with increasing experience and advances in imaging techniques, these complications have been addressed well [11].

The Myval™ transcatheter heart valve (THV) (Meril Life Sciences Pvt. Ltd., India) is a Conformité Européenne (CE)-marked, next-generation balloon-expandable (BE) TAVI system. It has demonstrated safety and efficacy for the treatment of severe AS in patients at low, intermediate and high risk for surgery [12,13]. Hitherto, clinical data related to the use of Myval™ THV in patients with symptomatic, severe AS is not available from Iraq. To dwell on this evidence, a real-world, prospective single-centre study was conducted on 100 patients who underwent TAVI with the Myval™ THV system to determine the early clinical outcomes.

## 2. Materials and methods

### 2.1. Study population

Patients with symptomatic severe AS who visited or were referred to the outpatient clinic of Al Najaf Cardiac Center, Iraq, during the period from January 2019 to January 2024 were included in the study. The study was performed in accordance with the Declaration of Helsinki and approved by the Institutional Ethics Committee. The inclusion criteria were symptomatic severe AS, high risk for surgical intervention and normal renal function. Patients with low-gradient “severe stenosis” (defined as aortic valve area  $<1.0 \text{ cm}^2$  and mean gradient less than 40 mmHg) were also included in the study population. Patients with very small aortic annular diameter ( $<18 \text{ mm}$ ), low surgical risk patients and patients with vascular prohibition were excluded. A total of 100 consecutive patients treated with Myval™ THV were evaluated for baseline characteristics, including medical history, clinical examination and electrocardiographic and echocardiographic data. All the patients provided written informed consent for the procedure and subsequent data were collected based on local practice. Either trans-thoracic or trans-esophageal

### Abbreviations:

AS	Aortic valve stenosis
AKI	Acute kidney injury
AV	Atrio-ventricular
BE	Balloon-expandable
CE	Conformité Européenne
CT	Computed tomography
MSCT	Multi-slice computed tomography
PET	Polyethylene terephthalate
PPI	Permanent pacemaker implantation
PVL	Paravalvular leak
PVR	Paravalvular regurgitation
SD	Standard deviation
STS	Society of Thoracic Surgeons
TAVI	Transcatheter aortic valve implantation
THV	Transcatheter heart valve

echocardiography was performed to confirm diagnosis and accurate calculation of aortic valve area, mean pressure gradient, valve morphology and left ventricle function. Severe AS was defined by aortic valve area  $<1 \text{ cm}^2$  and mean pressure gradient  $>40 \text{ mmHg}$ , and left ventricle dysfunction was defined by ejection fraction  $<55\%$ . The Society of Thoracic Surgeons (STS) score more than or equal to 8 was considered high. Aortic valve annulus diameters, degree of calcification in addition to coronary ostia height and implantation angle were exactly detected by multi-slice computed tomography (MSCT) of aortic root using 3mensio (Pie Medical Imaging, Maastricht, the Netherlands). Patients were followed up for 30 days through either clinically (in-hospital visit) or telephonically.

### 2.2. Myval™ THV device description

Myval is a next-generation balloon-expandable THV system. The device is structured on a nickel-cobalt alloy (MP35N) frame, which allows for optimal radial strength and radiopacity. The valve design is characterized by a unique honey-comb hybrid design cell structure comprising only one design element – a hexagon (large and small). The upper half of the frame (53% of expanded frame height) is composed of a large open-cell hexagonal configuration (clinical propensity to un-jail coronary ostia which preserves coronary flow); while the lower half of the frame (47% of expanded frame height) is composed of two short rows of close-cell hexagonal configuration providing high radial strength required at the annular base to ensure orthotopic valve fixation. The valve construction material is decellularized bovine pericardium tissue, crafted into a tri-leaflet valve, fixed towards the

valve outflow zone at three equipoised (separated at 120°) vertical commissural posts on the metal frame. The lower closed-cell part of the valve frame has an internal skirt made of polyethylene terephthalate (PET), which minimizes the propensity for para-valvular regurgitation (PVR). Additionally, the external skirt sits on the outer frame, which, eventually, on deployment, facilitates the plugging of micro-channels at the THV anchor site to further minimize PVR (Fig. 1).

Myval™ THV is delivered using a specially designed hi-flex, over-the-wire balloon catheter system - Navigator™ THV delivery system (Meril Life Sciences Pvt. Ltd., India). Myval is available in unique dimensional matrices ranging – from conventional (20, 23, 26 and 29 mm), intermediate (21.5, 24.5 and 27.5 mm), and extra-large (30.5 and 32 mm) sizes. The availability of the wide diameter range ensures optimal sizing of bioprosthetic valve to patient's computed tomography (CT)-derived annulus diameter, thus preserving the bioprosthetic valve geometry and respecting patient's aortic root complex. All diameters of Myval™ THV are compatible with 14 Fr Python introducer sheath (Meril Life Sciences Pvt. Ltd., India). Additionally, in case of a challenging anatomy where the operator is unable to cross the annulus, undeployed Myval™ THV can be fully retrieved through the Python sheath out of the patient.

During fluoroscopy, the crimped hexagonal cells of Myval™ THV over the Navigator™ delivery system appear as an alternative dark–light band-like pattern that facilitates the valve implantation procedure. The design and sizes of the Navigator™ THV delivery system are shown in Fig. 2. The

delivery system allows the flexion of the distal part, which lowers the risk of periprocedural strokes during arch navigation. The sub-annular depth of Myval™ THV across the diameter range is normally 3–3.5 mm. This shallow deployment of the valve does not affect the membranous septum, thus preventing a new conduction system disorder.

### 2.3. Procedural technique

The structural heart interventional team consisted of 2 trained operators, 2 nurses, a cath-lab technician and an anaesthetist. The study subjects underwent the TAVI procedure using Myval™ THV at a single-centre following the same protocol under local anaesthesia and conscious sedation with the transfemoral approach in all patients. The valves were deployed after pre-dilatation with rapid pacing technique. The valve deployment was done in coplanar view with 3 cusps equidistantly separated and in a straight line. The access site was closed by two 6F vascular closure devices (Perclose ProGlide™ system, Abbott Vascular, CA, USA).

### 2.4. Study endpoints

The endpoints, defined as per Valve Academic Research Consortium-3 were determined as in-hospital death, all-cause mortality, neurologic events, hospitalization (or re-hospitalization), bleeding and transfusion, vascular and access-related complications, cardiac structural complications, other procedural or valve-related complications, new conduction disturbances and arrhythmias, myocardial infarction, bioprosthetic valve dysfunction, clinically significant

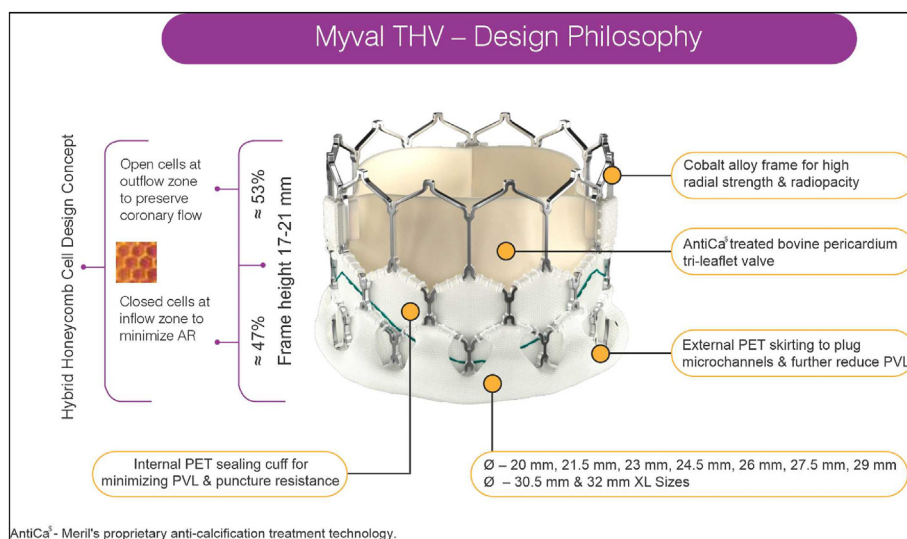


Fig. 1. Design and Salient Features of Myval™ THV. Abbreviation- THV: Transcatheter heart valve.

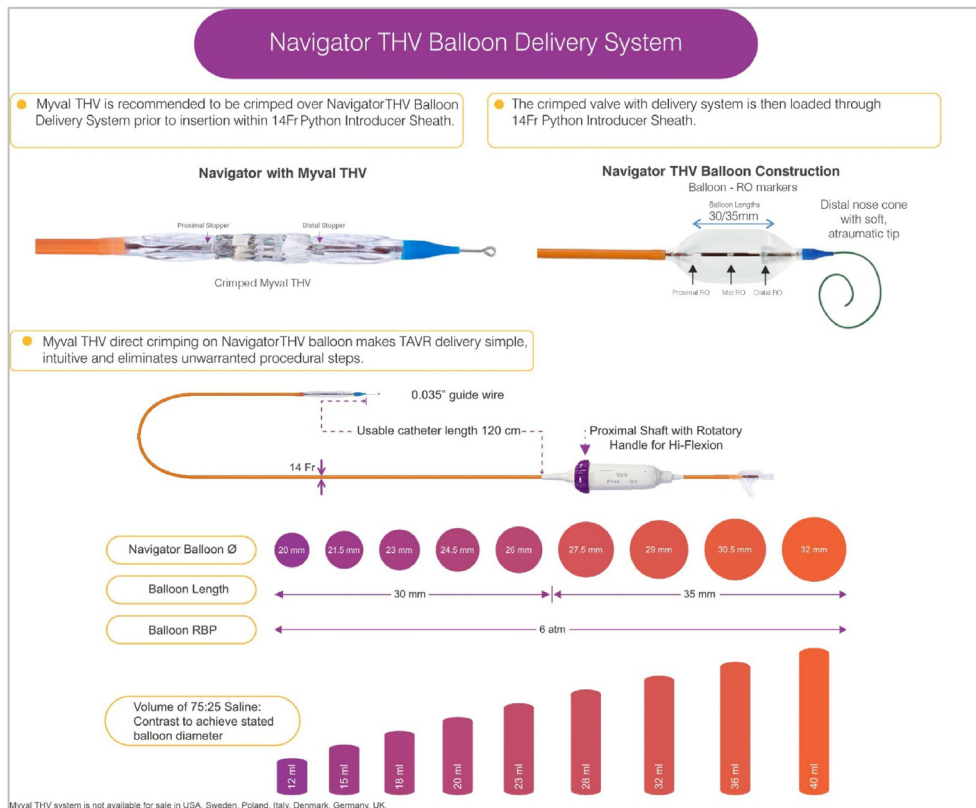


Fig. 2. Navigator™ THV Balloon Delivery System for Delivery of Myval™ THV. Abbreviation- THV: Transcatheter heart valve.

valve thrombosis, AKI, new permanent pacemaker implantation (PPI) and device success [14].

### 2.5. Statistical analysis

Data were analyzed using SPSS (version 23.0 for Linux®). Continuous data are presented as mean  $\pm$  standard deviation (SD) for parametric variables and median (interquartile range) for nonparametric variables. Categorical variables are presented as frequencies and percentages.

## 3. Results

### 3.1. Baseline characteristics and echocardiographic findings

The baseline demographic, laboratory and clinical characteristics of the patients are shown in Table 1. The mean age of the study population was  $73.8 \pm 6.5$  years, of which 50% were males. The most prevalent medical history (Table 1) was diabetes 77%, hypertension 67%, and coronary artery disease 43%. The mean ejection fraction was  $43.43 \pm 6.9\%$  while e-Glomerular filtration rate was  $60.38 \pm 9.47$  mL/min/1.73 m<sup>2</sup>.

### 3.2. Procedural details

All patients underwent TAVI procedure via the transfemoral route. Pre-dilatation was performed in all the patients. Fourteen patients (14%) required post-dilatation. Index hospital stay ranged from 2 to 5 days, with a median of 4 days. Table 2 presents the procedural details. Rapid pacing was achieved by the use of a temporary pacemaker in 72% of the

Table 1. Baseline Characteristics and Echocardiographic findings.

Variables	Values (N = 100)
Age, years, (mean $\pm$ SD)	$73.8 \pm 6.5$
Male, n (%)	50 (50.0)
STS risk score (%), (mean $\pm$ SD)	$4.1 \pm 1.6$
Diabetes mellitus, n (%)	77 (77.0)
Hypertension, n (%)	67 (67.0)
Coronary artery disease, n (%)	43 (43.0)
e-Glomerular filtration rate, mL/min/1.73m <sup>2</sup> (mean $\pm$ SD)	$60.38 \pm 9.47$
<b>Echocardiographic findings</b>	
Ejection fraction, % (mean $\pm$ SD)	$43.43 \pm 6.9$
Aortic valve annulus diameter, cm (mean $\pm$ SD)	$23.16 \pm 1.64$
Aortic valve area, cm <sup>2</sup> , (mean $\pm$ SD)	$0.7 \pm 0.1$
Mean pressure gradient, mmHg, (mean $\pm$ SD)	$46.8 \pm 6.6$

patients. Post-procedure mean pressure gradient was reduced to  $5.44 \pm 2.38$  mmHg versus  $46.8 \pm 6.6$  mmHg at pre-procedure.

The 24.5 mm valve size was deployed in 28% of patients; 25% had 26 mm, while 20% had 23 mm valve size. Median Myval™ THV size implanted was 24.5 mm. The frequency of valve sizes implanted is listed in Table 3. Intermediate sizes of Myval™ THV were used in 46% of the patients.

### 3.3. Clinical outcomes at 30-day

All-cause mortality (non-cardiac) was observed in one patient. Access site bleeding was noted in 11% of patients. Only 4% of patients had moderate paravalvular leak (PVL). Life-threatening bleeding and AKI did not occur in any patient. One patient had a stroke (transient and non-disabling) and 21% had conduction disturbances (with 7% of patients experiencing complete heart block). Only 6% had new PPI implantation. Table 4 depicts short-term clinical outcomes.

## 4. Discussion

This study is the only single-centre, real-world evidence-building data from Iraq that evaluated the clinical outcomes of the novel, balloon-expanding Myval™ THV in patients with severe symptomatic AS. The study was conducted on 100 consecutive patients with symptomatic severe AS. The mean age of the patients at this centre was  $73.8 \pm 6.5$  years, with an equal number of males and females. Nearly all patients had at least one of modifiable risk factors like diabetes 77%, hypertension 67% and coronary artery disease 43%. The mean e-glomerular filtration rate

Table 2. Procedural details.

Procedure details	N = 100
Pre-dilatation (%)	100.0
Post-dilatation (%)	14.0
Transfemoral access route (%)	100.0
Index hospital stay, days (median (range))	4 (2–5)

Table 3. Myval transcatheter heart valve sizes implanted.

Myval™ THV Size (mm)	n (%)
20	2 (2.0)
21.5	5 (5.0)
23	20 (20.0)
24.5	28 (28.0)
26	25 (25.0)
27.5	13 (13.0)
29	7 (7.0)
Median	24.5

Abbreviation- THV: Transcatheter heart valve.

Table 4. Thirty-day clinical outcomes.

Complications (N = 100)	n (%)
Death (non-cardiac)	1 (1.0)
Stroke	1 (1.0)
Coronary occlusion	0.0
Access site bleeding	11 (11.0)
New Permanent Pacemaker Implantation	6 (6.0)
Paravalvular leak	
Mild	26 (26.0)
Moderate	4 (4.0)
Conduction disturbances	
Absent	79 (79.0)
Left bundle branch block	12 (12.0)
First-degree heart block	2 (2.0)
Complete heart block	7 (7.0)

was  $60.38 \pm 9.47$  mL/min/1.73 m<sup>2</sup>. Pre-procedure echocardiographic findings revealed a low left ventricular ejection fraction of  $43.43 \pm 6.9\%$ . All patients underwent TAVI under the transfemoral access route. Pre-dilatation of the native aortic valve was performed in all the patients and 14% required post-dilatation. All patients had a reasonable length of hospital stay, which ranged from 2 to 5 days.

Since Myval™ THV is available in conventional, intermediate, and extra-large sizes, it enables interventional cardiologists to choose the most appropriate valve size. In a retrospective survey conducted in 27 countries on 1115 patients who underwent Myval™ THV implantation, it was demonstrated that intermediate sizes of Myval™ THV were used in 42% of patients. In this real-world evidence study, 46% of patients had conventional sizes (20, 23, 26 and 29 mm), and 54% had intermediate (21.5, 24.5 and 27.5 mm), addressing the unmet need for interventional cardiologists for a range of more calibrated THV sizing [15]. Extra-large (30.5 and 32 mm) Myval™ THV was not implanted in any patient. This size matrix has been shown to reduce the oversizing/undersizing ratio to suit anatomical requirements, thereby reducing the incidence of potential catastrophic complications.

The immediate and short-term clinical outcomes/complications of this study included death – noncardiac (1%), stroke (transient and non-disabling) (1%), access site bleeding (11%), conduction abnormalities and moderate PVL which were comparable to international registries. According to Burak Can Depboylu et al. (2018) occurrence of PVLs can be explained by 3 mechanisms: prosthetic valve-annulus size mismatch; inappropriate placement of the prosthetic valve; and incomplete apposition of the valve due to deformed native structure, however it is not related to patient age [16]. In the present study, 70% of the patients had no PVLs while 26% had mild and only 4% had moderate leaks which were not age

related, evidencing the good valve size matching and placement. Similar findings were published in the EVAL registry performed on a retrospective analysis of 166 consecutive patients undergoing TAVI with either Myval™ THV (n = 58) or Evolut R THV (n = 108), wherein Myval™ THV group had a significant lower incidence of moderate PVL (6.9% versus 19.8%, p = 0.039) and PPI (11% versus 27.5%, p = 0.02) [17]. Another complication associated with TAVI is conduction abnormalities whose incidence varies between 5.7% and 42.5% [18]. The incidence of atrioventricular (AV) block varies between 24.5% and 25.8% for CoreValve® and 5.9%–6.5% for Edwards SAPIEN® balloon-expandable valve [19]. The present study reported conduction abnormalities in only 21% of its patients, including complete heart block in 7% of patients, while 12% had left bundle branch block. Thirty-day outcomes of the current study are comparable with the findings reported in PARTNER 3 trial in which low-risk patients were included [20].

Mortality rates following TAVI varies between 4.34% and 24% in various trials like PARTNER 1A, COREVALVE, NOTION and SURTAVI trials [19]. There was only one death in this study. Literature reports no significant difference in mortality between self-expandable and BE prosthetic valve implantation [21]. The cardiac cause of death (75%) occurs in the first 48 h following the procedure while after the first 48 h, non-cardiac reasons are the most common one with an incidence of 69% [22]. Two ongoing prospective, large, randomized studies: the LAND-MARK trial and the COMPARE-TAVI trial are evaluating the performance and long-term durability of commonly used self-expandable and BE THV which will further infer its potential [23,24]. Longer-term follow-up and ongoing randomized controlled trials and real-world registries with the Myval™ THV are expected to further support the safety and efficacy, and to expand its indication across the world.

## 5. Conclusion

The use of Myval™ THV at a single-centre in Iraq in patients with native symptomatic severe AS established that TAVI is a safe and reliable treatment procedure for high and intermediate-surgical risk patients. Its early outcomes establish the appropriate patient selection, procedural success, and good clinical outcomes.

## Author contribution

Conception and design of Study: KA, AJM. Acquisition of data: KA, AJM. Analysis and interpretation of data: KA, AJM. Research investigation

and analysis: KA, AJM. Data collection: KA, AJM. Drafting of manuscript: KA. Revising and editing the manuscript critically for important intellectual contents: KA, AJM. Data preparation and presentation: KA. Supervision of the research: KA. Research coordination and management: KA, AJM.

## Funding

The primary funder is MERIL THV company.

## Conflicts of interest

None declared.

## Acknowledgement

None.

## References

- [1] Manning WJ. Asymptomatic aortic stenosis in the elderly: a clinical review. *JAMA* 2013;310(14):1490–7. <https://doi.org/10.1001/jama.2013.279194>. PMID: 24104373.
- [2] Czarny MJ, Resar JR. Diagnosis and management of valvular aortic stenosis. *Clin Med Insights Cardiol* 2014;8(Suppl 1): 15–24. <https://doi.org/10.4137/CMC.S15716>. PMID: 25368539; PMCID: PMC4213201.
- [3] Spaccarotella C, Mongiardo A, Indolfi C. Pathophysiology of aortic stenosis and approach to treatment with percutaneous valve implantation. *Circ J* 2011;75(1):11–9. <https://doi.org/10.1253/circj.cj-10-1105>. PMID: 21178291.
- [4] Abdel-Wahab M, Jose J, Richardt G. Transfemoral TAVI devices: design overview and clinical outcomes. *Euro-Intervention* 2015;11(Suppl W):W114–8. <https://doi.org/10.4244/EIJV11SWA33>. PMID: 26384175.
- [5] Tzemos N, Therrien J, Yip J, Thanassoulis G, Tremblay S, Jamorski MT, et al. Outcomes in adults with bicuspid aortic valves. *JAMA* 2008;300(11):1317–25. <https://doi.org/10.1001/jama.300.11.1317>. PMID: 18799444.
- [6] Hughes BR, Chahoud G, Mehta JL. Aortic stenosis: is it simply a degenerative process or an active atherosclerotic process? *Clin Cardiol* 2005;28(3):111–4. <https://doi.org/10.1002/clc.4960280303>. PMID: 15813615; PMCID: PMC6654342.
- [7] Namisaki H, Nagata Y, Seo Y, Ishizu T, Izumo M, Akashi YJ, et al. Symptomatic paradoxical low gradient severe aortic stenosis: a possible link to heart failure with preserved ejection fraction. *J Cardiol* 2019;73(6):536–43. <https://doi.org/10.1016/j.jcc.2018.12.017>. Epub 2019 Jan 5. PMID: 30617000.
- [8] Manjunath CN, Srinivas P, Ravindranath KS, Dhanalakshmi C. Incidence and patterns of valvular heart disease in a tertiary care high-volume cardiac center: a single center experience. *Indian Heart J* 2014;66(3):320–6. <https://doi.org/10.1016/j.ihj.2014.03.010>. Epub 2014 Apr 14. PMID: 24973838; PMCID: PMC4121759.
- [9] Cribier A, Eltchaninoff H, Bash A, Borenstein N, Tron C, Bauer F, et al. Percutaneous transcatheter implantation of an aortic valve prosthesis for calcific aortic stenosis: first human case description. *Circulation* 2002;106(24):3006–8. <https://doi.org/10.1161/01.cir.0000047200.36165.b8>. PMID: 12473543.
- [10] Leon MB, Smith CR, Mack MJ, Makkar RR, Svensson LG, Kodali SK, et al. PARTNER 2 investigators. Transcatheter or surgical aortic-valve replacement in intermediate-risk patients. *N Engl J Med* 2016;374(17):1609–20. <https://doi.org/10.1056/NEJMoa1514616>. Epub 2016 Apr 2. PMID: 27040324.
- [11] Smith CR, Leon MB, Mack MJ, Miller DC, Moses JW, Svensson LG, et al. PARTNER Trial Investigators. Transcatheter versus surgical aortic-valve replacement in high-risk

- patients. *N Engl J Med* 2011;364(23):2187–98. <https://doi.org/10.1056/NEJMoa1103510>. Epub 2011 Jun 5. PMID: 21639811.
- [12] Akyüz AR, Konaş AH, Çorakoğlu ÖF, Şahin S, Kul S, Korkmaz L. First experiences with a new balloon-expandable Myval transcatheter aortic valve: a preliminary study. *Herz* 2022;47(5):449–55. <https://doi.org/10.1007/s00059-021-05069-4>. Epub 2021 Oct 13. PMID: 34643745; PMCID: PMC8512594.
- [13] Ad N, Holmes SD, Patel J, Pritchard G, Shuman DJ, Halpin L. Comparison of EuroSCORE II, original EuroSCORE, and the society of thoracic Surgeons risk score in cardiac surgery patients. *Ann Thorac Surg* 2016;102(2):573–9. <https://doi.org/10.1016/j.athoracsur.2016.01.105>. Epub 2016 Apr 23. PMID: 27112651.
- [14] García-Gómez M, Delgado-Arana JR, Halim J, De Marco F, Trani C, Martin P, et al. Next-generation balloon-expandable Myval transcatheter heart valve in low-risk aortic stenosis patients. *Cathet Cardiovasc Interv* 2022;99(3):889–95. <https://doi.org/10.1002/ccd.29923>. Epub 2021 Aug 14. PMID: 34390296.
- [15] VARC-3 WRITING COMMITTEE, Généreux P, Piazza N, Alu MC, Nazif T, Hahn RT, Pibarot P, et al. Valve academic Research Consortium 3: updated endpoint definitions for aortic valve clinical Research. *J Am Coll Cardiol* 2021;77(21):2717–46. <https://doi.org/10.1016/j.jacc.2021.02.038>. Epub 2021 Apr 19. PMID: 33888385.
- [16] Généreux P, Head SJ, Hahn R, Daneault B, Kodali S, Williams MR, et al. Paravalvular leak after transcatheter aortic valve replacement: the new Achilles' heel? A comprehensive review of the literature. *J Am Coll Cardiol* 2013;61(11):1125–36. <https://doi.org/10.1016/j.jacc.2012.08.1039>. Epub 2013 Jan 30. PMID: 23375925.
- [17] Barki M, Ielasi A, Buono A, Maliandi G, Pellicano M, Bande M, et al. Clinical comparison of a novel balloon-expandable versus a self-expanding transcatheter heart valve for the treatment of patients with severe aortic valve stenosis: the EVAL registry. *J Clin Med* 2022;11(4):959. <https://doi.org/10.3390/jcm11040959>. PMID: 35207232; PMCID: PMC8876233.
- [18] Bates MG, Matthews IG, Fazal IA, Turley AJ. Postoperative permanent pacemaker implantation in patients undergoing trans-catheter aortic valve implantation: what is the incidence and are there any predicting factors? *Interact Cardiovasc Thorac Surg* 2011;12(2):243–53. <https://doi.org/10.1510/icvts.2010.256578>. Epub 2010 Nov 23. PMID: 21098508.
- [19] Nazif TM, Dizon JM, Hahn RT, Xu K, Babaliaros V, Douglas PS, et al., PARTNER Publications Office. Predictors and clinical outcomes of permanent pacemaker implantation after transcatheter aortic valve replacement: the PARTNER (Placement of AoRtic TraNscatheter Valves) trial and registry. *JACC Cardiovasc Interv* 2015;8(1 Pt A):60–9. <https://doi.org/10.1016/j.jcin.2014.07.022>. PMID: 25616819.
- [20] Mack MJ, Leon MB, Thourani VH, Makkar R, Kodali SK, Russo M, et al., PARTNER 3 Investigators. Transcatheter aortic-valve replacement with a balloon-expandable valve in low-risk patients. *N Engl J Med* 2019;380(18):1695–705. <https://doi.org/10.1056/NEJMoa1814052>. Epub 2019 Mar 16. PMID: 30883058.
- [21] Smith CR, Leon MB, Mack MJ, Miller DC, Moses JW, Svensson LG, et al. PARTNER Trial Investigators. Transcatheter versus surgical aortic-valve replacement in high-risk patients. *N Engl J Med* 2011;364(23):2187–98. <https://doi.org/10.1056/NEJMoa1103510>. Epub 2011 Jun 5. PMID: 21639811.
- [22] Van Mieghem NM, van der Boon RM, Nuis RJ, Schultz C, van Geuns RJ, Serruys PW, et al. Cause of death after transcatheter aortic valve implantation. *Cathet Cardiovasc Interv* 2014;83(7):E277–82. <https://doi.org/10.1002/ccd.24597>. Epub 2013 Nov 30. PMID: 22887941.
- [23] Kawashima H, Soliman O, Wang R, Ono M, Hara H, Gao C, et al. Rationale and design of a randomized clinical trial comparing safety and efficacy of Myval transcatheter heart valve versus contemporary transcatheter heart valves in patients with severe symptomatic aortic valve stenosis: the LANDMARK trial. *Am Heart J* 2021;232:23–38. <https://doi.org/10.1016/j.ahj.2020.11.001>. Epub 2020 Nov 6. PMID: 33160946.
- [24] Seth A, Kumar V, Singh VP, Kumar D, Varma P, Rastogi V. Myval: a novel transcatheter heart valve for the treatment of severe aortic stenosis. *Intervent Cardiol* 2023;18:e12. <https://doi.org/10.15420/icr.2020.32>. PMID: 37398875; PMCID: PMC10311401.