






# Performance of the 32 mm Myval transcatheter heart valve for treatment of aortic stenosis in patients with extremely large aortic annuli in real-world scenario: First global, multicenter experience

Andreas Holzamer MD<sup>1</sup>  | Francesco Bedogni MD<sup>2</sup>  | Pieter van Wyk MD<sup>3</sup> | Parag Barwad MD<sup>4</sup>  | Marcin Protasiewicz MD<sup>5</sup> | Alfonso Ielasi MD, FESC<sup>6</sup>  | Luis Nombela-Franco PhD<sup>7</sup>  | Tim Seidler MD, MHBA<sup>8</sup> | Michael Hilker MD<sup>1</sup>

<sup>1</sup>University of Regensburg Medical Center, Regensburg, Germany

<sup>2</sup>IRCCS Policlinico San Donato, Milano, Italy

<sup>3</sup>Department of Cardiology, Netcare Sunninghill Hospital, Sunninghill, South Africa

<sup>4</sup>Department of Cardiology, Postgraduate Institute of Medical Education and Research, Chandigarh, India

<sup>5</sup>Cardiology Department, Wroclaw Medical University, Wroclaw, Poland

<sup>6</sup>Clinical and Interventional Cardiology Unit, Istituto Clinico Sant'Ambrogio, Milan, Italy

<sup>7</sup>Cardiovascular Institute, Hospital Clínico San Carlos, Madrid, Spain

<sup>8</sup>Clinic for Cardiology and Pneumology, University Medical Center Göttingen, Göttingen, Germany

## Correspondence

Andreas Holzamer, MD, University of Regensburg Medical Center, Regensburg, Germany.

Email: [andreas.holzamer@ukr.de](mailto:andreas.holzamer@ukr.de)

## Abstract

**Background:** Extremely large aortic valve anatomy is one of the remaining limitations leading to exclusion of patients for transcatheter aortic valve replacement (TAVR).

**Aims:** The newly approved Myval 32 mm device is designed for use in aortic annulus areas up to 840 mm<sup>2</sup>. Here we want to share the initial worldwide experience with the device.

**Methods and Results:** Retrospective data were collected from 10 patients with aortic stenosis and very large annular anatomy (mean area 765.5 mm<sup>2</sup>), who underwent implantation with 32 mm Myval transcatheter heart valve at eight centers. Valve Academic Research Consortium-2 device success was achieved in all cases. Mild paravalvular leak was observed in three patients and two patients required new pacemaker implantation. One patient experienced retroperitoneal hemorrhage caused by the contralateral 6 F sheath and required surgical revision. No device-related complications, stroke, or death from any cause occurred within the 30-day follow-up period. In a studied cohort of 2219 consecutive TAVR-screened patients from a central European site, only 0.27% of patients showed larger anatomy than covered by the 32 mm Myval device by instructions for use without off-label use of overexpansion. This rate was significantly higher for the 34 mm Evolut Pro (1.8%) and 29 mm Sapien 3 (2.1%) devices.

**Conclusions:** The Myval 32 mm prosthesis showed promising initial results in a cohort of patients who previously had to be excluded from TAVR. It is desirable that

**Abbreviations:** AS, aortic stenosis; MSCT, multislice computed tomography; PVL, paravalvular leakage; SAVR, surgical aortic valve replacement; TAVR, transcatheter aortic valve replacement; THV, transcatheter heart valve.

The study was registered at the University of Regensburg Center for Clinical Studies (Z-2021-1582-9).

This is an open access article under the terms of the Creative Commons Attribution-NonCommercial-NoDerivs License, which permits use and distribution in any medium, provided the original work is properly cited, the use is non-commercial and no modifications or adaptations are made.

© 2023 The Authors. *Catheterization and Cardiovascular Interventions* published by Wiley Periodicals LLC.

all future TAVR systems accommodate larger anatomy to allow optimal treatment of all patients.

#### KEYWORDS

aortic valve disease, new devices (in general), percutaneous valve therapy

## 1 | INTRODUCTION

Transcatheter aortic valve replacement (TAVR) is an established treatment alternative to surgical aortic valve replacement (SAVR) in patients with severe aortic stenosis (AS) at intermediate-, high-, or prohibitive-surgical risk.<sup>1-3</sup> Noninferiority of TAVR as compared with SAVR in patients with severe AS, who are at low-surgical risks, has further increased its adoption across the globe.<sup>4-6</sup> Moreover, with the evolution of technology, more complex anatomy such as bicuspid valves and heavy calcified leaflets have been successfully treated with this less invasive approach. However, a considerable number of patients screened for TAVR still has to be excluded due to unsuitable anatomy. One of the most common exclusion criteria for the therapy is too large anatomy of the aortic annulus. The largest available current standard devices are limited to an annular area of 683 mm<sup>2</sup> (Sapien 3, Edwards) and annular perimeter of 94.2 mm (Evolut R, Medtronic, USA) by manufacturer's instructions for use.

The Myval transcatheter heart valve (THV) (Meril Life Sciences Pvt. Ltd) is a new-generation balloon-expandable device that has been granted CE mark approval in 2020 after demonstrating safety and efficacy for treatment of severe symptomatic native aortic stenosis in intermediate and high-risk patients.<sup>7</sup> To address the concern of size limitation of the currently available THV portfolio, a wide range of sizes of the device has been developed including extra-large sized Myval THV (30.5 mm and 32 mm). To the best of our knowledge, the 32 mm Myval THV is the largest available aortic THV as it covers annular areas of 700–840 mm<sup>2</sup>. Herein, we share our early experiences with use of the 32 mm Myval THV for extremely large aortic annuli to determine procedural feasibility and acute clinical performance of the device in this patient population.

## 2 | METHODS

### 2.1 | Study design

This retrospective, multicenter observational study compiled data of 10 patients who underwent TAVR with the implantation of the 32 mm Myval THV for treatment of severe native aortic stenosis at eight different TAVR centers located in Germany, India, Italy, Poland, South Africa, and Spain.

A multidisciplinary heart team of each participating center evaluated the patients for eligibility of the TAVR procedure. Patients who were treated with TAVR for pure aortic valve insufficiency or transcatheter valve-in-valve implantation were excluded from the

study. Preprocedural work-up included assessment of severity of aortic stenosis using transthoracic echocardiography and determination of aortic root dimensions using multislice computed tomography (MSCT).

Procedural success, in-hospital and 30-day follow-up events are described as defined by the Valve Academic Research Consortium-2 (VARC-2) consensus document.<sup>8</sup>

Furthermore, computed tomography (CT) sizing data from the University of Regensburg transcatheter aortic valve implantation (TAVI) database was used to describe the frequency of extra-large annuli in a central European cohort. All sizing data for patients planned for TAVR in the center is prospectively collected in this database. It is important to emphasize that the data set includes all screened, and not only actually performed TAVR cases. Furthermore, no patients of the cohort were excluded due to anatomical reasons without undergoing CT screening. This is thus a representative cohort in which, to the best of our knowledge, any preselection bias due to anatomical contraindications can be excluded.

A total of 2219 consecutive patients who underwent TAVR screening between 2012 and 2020 were identified. The evaluation of the MSCTs was performed according to the standard recommendations.<sup>9</sup> Statistical analysis was performed using the Medcalc software (Medcalc Software Ltd). Normal distribution of sizing data was tested using the Shapiro–Wilk test. The nonparametric two-sided Mann–Whitney *U* test was used to examine nonnormally distributed sizing data.

The study was registered at the University of Regensburg Center for Clinical Studies (Z-2021-1582-9). Explicit ethics committee board approval could be waived according to European regulations due to the noninvasive retrospective character of the study.

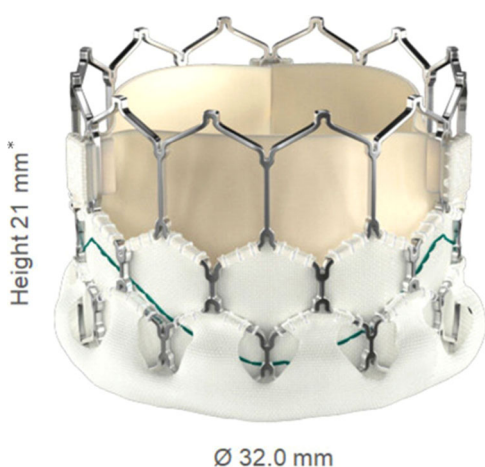
### 2.2 | Study device

The design features of the Myval THV have been described previously.<sup>10</sup> In brief, the Myval THV is a bovine pericardial tri-leaflet balloon-expandable THV system. It is structured on a nickel-cobalt alloy frame, which provides radial strength and radiopacity to the valve. The hybrid honeycomb design of the THV frame is characterized by the combination of open cells (53% of the frame toward inflow tract) and closed cells (47% of the frame toward the outflow tract) as shown in Figure 1. Myval THV was designed to provide high radial strength at the annulus, while open cells prevent coronary obstruction and provide accessibility for catheterization. The decellularized bovine pericardium tissue valve is mounted on a

metal frame. The internal and external skirting, composed of polyethylene terephthalate, retards deposition of calcium (which may damage the bioprosthetic valve tissue) and aids in minimizing the propensity for paravalvular leak (PVL). The valve is delivered with a flexible, over-the-wire balloon catheter delivery system, Navigator THV delivery system (Meril Life Sciences Pvt. Ltd).

Based on the findings from MSCT, an appropriate size of the THV is manually crimped on the Navigator balloon using a mechanical crimping tool, Val-de-Crimp (Meril Life Sciences Pvt. Ltd).

The Myval THV is available in conventional sizes (20, 23, 26, and 29 mm), intermediate sizes (21.5, 24.5, and 27.5 mm), and extra large sizes (30.5 and 32 mm). The inclusion of intermediate sizes and extra large sizes of THVs in the size matrix of Myval intends to provide greater flexibility to the heart team to choose the optimal sizing



**FIGURE 1** Expanded Myval 32 mm with a nominal area of 804 mm<sup>2</sup>.

without the need of empirical excessive under- or oversizing. This might improve clinical outcomes as different studies have established that inappropriate THV sizing is associated with adverse events such as annular rupture, prosthesis embolization, patient-prosthesis mismatch, paravalvular regurgitation, or significant conduction disturbances.<sup>11–15</sup>

The Myval THV system is currently commercially available in India, Latin America, CIS, South East Asia, Middle East, and Europe (except Germany, Denmark, Italy, UK, France, Poland, Ireland, and Sweden).

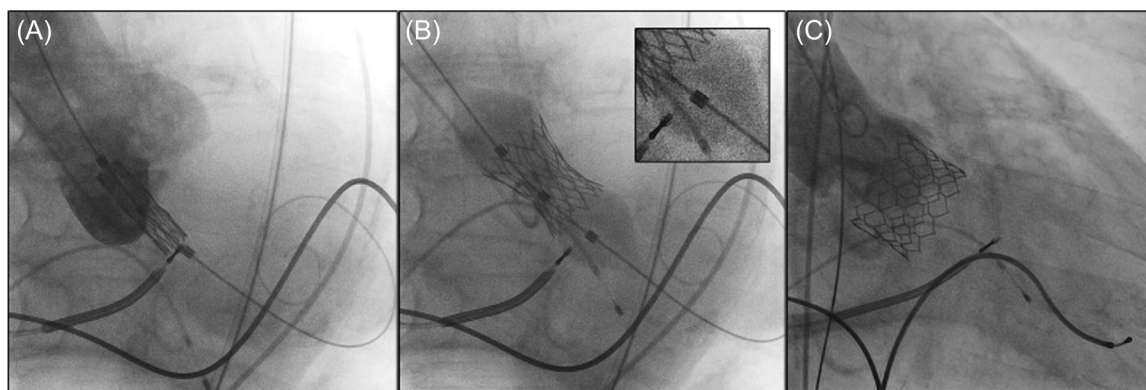
## 2.3 | Implantation procedure

All procedures were performed by experienced TAVR operators. However, experience regarding the implantation of the Myval THV was limited as the device is only newly available. In addition, the procedure was the first ever use of the Myval system in the local center in two of the cases. The indication for pre- and postdilatation was set according to the center's best practice. Implantations were performed under rapid overpacing. Figure 2 illustrates the implantation procedure in detail. Following removal of the delivery system and access site sheath, the arteriotomy was closed according to the center's common routine practice.

## 3 | RESULTS

### 3.1 | Summary of procedural outcome

All 10 patients included in the evaluation were male. Patient's age ranged from 66 to 90 years. Eight patients were treated for tricuspid



**FIGURE 2** Implantation of the 32 mm Myval. (A) Initial positioning. The middle of the second dense marker band of the crimped prosthesis is positioned in projection to the aortic valve annulus. (B) Implantation. The implantation is performed under rapid overpacing. Notice the dog-bone shaped opening characteristic that is created by the separated proximal and distal inflow ports. This mechanism is intended to stabilize the implantation. The solid conical spacers are visible as a contrast cavity in fluoroscopy (upper right panel). These spacers are mounted on the delivery system within the inflation balloon and prevent dislocation of the crimped prosthesis from the implantation balloon during delivery, retrieval or fine positioning while implanting. In addition, the proximal spacer allows retrieval through the expandable sheath by re-expansion of the sheath. (C) Final result. The angiogram in an RAO projection shows an intended implantation height and sufficient sealing without detectable paravalvular leakage.

aortic valve disease and two patients for bicuspid aortic valve disease (both Sievers type I R/L). Pre-operative MSCT assessment revealed an average annular area of 765.5 mm<sup>2</sup> (712–822 mm<sup>2</sup>). Table 1 summarizes further baseline clinical characteristics, preprocedural echocardiographic, and MSCT findings of the study population.

Although the device can be implanted retrogradely via transapical access or antegrade alternative accesses, all cases in this series were suitable for transcatheter transfemoral approach with the 14F expandable Python sheath (Meril Life Sciences Pvt. Ltd). Implantation was performed by center's choice under conscious sedation in six of the cases, whereas four cases were under general anesthesia.

In nine of 10 patients, preballoon valvuloplasty with a 25 mm Mammoth balloon catheter (Meril Life Sciences Pvt. Ltd) was performed under rapid overpacing. Post-dilatation with the Navigator delivery system was performed in one case to overcome mild PVL that could be successfully eliminated. The arteriotomy caused by the 14F Python sheath was closed using the Proglide device (Abbott) in eight cases or the MANTA vascular closure device (Essential Medical Inc.) in two cases.

VARC-2 device success was achieved in all patients.

Echocardiography was performed during the procedure and before discharge in all patients. Three patients showed mild PVL at discharge and the seven remaining patients showed no PVL. The mean transprosthetic gradient at discharge was 5.6 mmHg on average, with a maximum of 9 mmHg in two patients.

Implantation of a pacemaker device within the index hospital stay was necessary in two cases. Underlying reason was complete AV block in one and persisting bradyarrhythmia in the other case. One more patient showed a new-onset LBBB after TAVR procedure without an indication for pacemaker implantation.

Two patients suffered vascular complications: Patient 3 developed a retroperitoneal hematoma caused by a failure or a small-bore closure device (AngioSeal) that was used on the contralateral femoral site of the TAVI access to close the 6F pigtail insertion sheath. The hematoma was surgically treated in a second procedure. The event was classified as not device-related major vascular event. Patient 6 was treated for a pseudoaneurysm at the access site by manual compression. The event has to be considered device-related and a minor vascular complication. Both patients fully recovered without sequelae.

Thirty-day follow-up is available for all 10 patients. No further VARC-2 events occurred within the follow-up period (Table 2).

### 3.2 | Frequency of large anatomy

The distribution of annular areas of the 2219 patients screened for TAVR is illustrated in Figure 3A. Shapiro-Wilk test rejected normal distribution ( $p < 0.0001$ ) of annular area in the whole cohort as well as in gender-specific and the tricuspid patients' subcohorts.

Too large anatomy was found to be the most common cause of anatomic contraindication to TAVI in the studied population,

accounting for 45% of the total excluded cases before the availability of 32 mm Myval THV (Figure 4).

The frequency with which patients had an anatomy that was too large for the currently available largest prosthesis models (Sapien 3 29 mm, Evolut R 34 mm and Myval 34 mm) was also analyzed. The manufacturers' sizing specifications were used for this purpose, which say that the balloon-expandable models (Sapien, Myval) should be chosen according to the annular area, while the annular perimeter is used for the self-expanding Evolut R prosthesis.

For ease of comparison, the derived diameters, which are calculated using the circular formula, are given below for the different prostheses.

In 46 patients (2.1%), the annular area exceeded 680 mm<sup>2</sup> (area-derived diameter of 29.4 mm), which is the upper sizing recommendation for the 29 mm Sapien 3 device. Of these, only three patients were female (6.5%). In contrast, 1118 patients (50.4%) of the whole cohort were female.

The 34 mm Evolut R THV is the largest commonly available device. According to the manufacturer's recommendations, an aortic annulus perimeter of 94.2 mm (perimeter-derived diameter of 30.0 mm) was set as the upper limit for the device suitability. This results in a total of 39 patients (1.8%) with too large aortic annular perimeter including one female subject of the total studies cohort.

The 32 mm Myval THV with its upper size range of 840 mm<sup>2</sup> (area-derived diameter of 32.7 mm) was able to cover all but six patients (0.3%) in the cohort, all of whom were male.

Accordingly, 84.6% of patients with too large anatomy for conventional prosthesis could have been treated within the sizing recommendations with the 32 mm Myval device. The overall rate of excluded cases could have been reduced by 38.0% using the Myval 32 mm prosthesis.

Patients with bicuspid anatomy of any subtype showed significantly larger anatomy than tricuspid patients in the Mann-Whitney rank sum test (median 525 vs. 457 mm,  $p < 0.0001$ ). Annular area above the upper sizing recommendation threshold of the 32 mm Myval THV (840 mm<sup>2</sup>) was associated with bicuspid anatomy in four of six patients (66%), whereas this rate was 31% (11 of 35) for patients above the Sapien 3% and 32% (12/38) above the Evolut R sizing recommendations.

## 4 | DISCUSSION

The present study provides early user experience of the 32 mm Myval THV for treatment of extremely large aortic annuli in a small cohort of patients.

Feasibility of the implantation procedure was demonstrated as VARC-2 device success could be achieved in all cases. Furthermore, none of the patient experienced relevant procedural complications, except one patient who suffered a retroperitoneal hematoma. However, as the hematoma was caused by failure of a 6F-closure device used for sealing the pigtail insertion sheath on the

TABLE 1 Baseline data.

	Pat. 1	Pat. 2	Pat. 3	Pat. 4	Pat. 5	Pat. 6	Pat. 7	Pat. 8	Pat. 9	Pat. 10	Mean	SD
Age (years)	66	79	90	76	68	76	75	78	71	82	76.1	7.0
Gender	M	M	M	M	M	M	M	M	M	M	All male	
Weight/height/body surface area (m <sup>2</sup> )	73/178/1.95	172/60/1.9	173/61/1.9	110/172/2.21	175 cm/80 kg/1.81	187/78/2.85	92/175/2.14	73/172/1.87	80/178/1.99	178/67/1.8	77.4/176/2.04	14.94/4.62/0.31
Relevant coexistent medical conditions	CABG and PCI for CAD; heart failure; paroxysmal AF; dilated left ventricle, pulmonary hypertension	COPD; CKD-II; CAD; Hip replacement	aHT; CRT-D; OSAS with nCPAP; ileum resection; CKD; PCI for CAD; aFib with NOAK	CKD, BPH, severe COPD, RHD	Hypertension, DM-2, AV-nodal re-entrant tachycardia	Paroximal aFib, CKD, critical right internal carotid artery disease	DM-2, aHT, pulmonary Fibrosis, pulmonary hypertension	Diabetes, aHT, COPD	aHT	aHT; CKD-II		
Pre-OP ECG	NSR	RBBB, LAHB	CRT paced	AF	SR, AV-B I	SR, AV-B I, LBBB	AF, incomplete LBBB	NSR	NSR	SR, AV-BI, RBBB		
NYHA grade	II	III	III	III-IV	II	II	III-IV	III	III	III		
EuroScore II/STS %	39.57/2.51	3.09/5.05	5.83/2.14	4.15/4.1	0.53/0.54	2.01/1.17	2.61/3.1	n.a./2.5	n.a./2.0	3.23/2.84	7.63/2.66	13.00/1.37
Echocardiography-relevant findings	AS III	AS III, AR II	LFLG-AS III, AR I, MR II, TR II	AS III	AS III, AR I, MR I	AS III	AS III; MR I; TR I	AS III, AR I, MR I	AS III; AR III	AS III, AR I, MR I		
Mean aortic valve gradient, mmHg	44	51	21	45	42	60	43	40	42	46	46.4	9.8
Aortic valve area, cm <sup>2</sup>	0.8	0.76	0.4	0.6	1.02	0.8	0.72	n.a.	0.94	0.68	0.75	0.18
Left ventricular ejection fraction, %	25	44	45	55	55	55	40	62	54	45	48	10.8
Valve anatomy (tricuspid/bicuspid)	Tricuspid	Tricuspid	Tricuspid	Bicuspid I R/L	Tricuspid	Tricuspid	Tricuspid	Tricuspid	Tricuspid	Bicuspid		
Area-derived diameter, mm	31.9	30.1	31.0	32.4	30.2	30.2	30.1	32.3	32.3	31.4	31.2	1.0
Annulus area, mm <sup>2</sup>	800	712	755	822	718	718	712	820	820	775	765.2	48.0
Perimeter-derived diameter, mm	32.1	30.4	31.4	32.5	30.9	30.6	30.5	31.9	32.6	32.3	31.5	0.9
RCA/LCA height, mm	14.2/16.2	21.5/9.7	18.8/18.9	22.5/20.3	18.0/16.0	20.6/19.2	13/9	21.8/10.8	26.6/22.3	18.8/20.7	20.9/16.3	5.6/4.9
LVOT diameter, mm	33	31.3	31.8	31.6	31.6	30.5	31.1	33.5	29.4	31.9	31.8	1.0

TABLE 1 (Continued)

	Pat. 1	Pat. 2	Pat. 3	Pat. 4	Pat. 5	Pat. 6	Pat. 7	Pat. 8	Pat. 9	Pat. 10	Mean	SD
Sinotubular junction diameter, mm	37.4	31.6	32.2	40.9	31.1	33.7	31.6	n.a.	n.a.	34.7	34.0	3.5
Sinus of valsalva diameter, mm (L/R/N)	40.4/33.7/39.8	35.8/32.0/37.9	41.7/37.7/41.5	41.4/40.6/43.5	35.2/33.3/35.0	40.5/37.6/41.6	39.2/35.5/39.5	n.a.	n.a.	39.7/42.8/44.7	39.2/36.7/40.4	2.4/3.7/3.1
Eccentricity index	0.18	0.12	0.18	0.19	0.25	0.22	0.21	0.20	0.19	0.31	0.20	0.05

Note: Pre-operative gradients were measured by echocardiography. Anatomical measurements of the aortic valve complex as area, perimeter, LVOT diameter, sinus of valsalva, sinotubular junction and coronary distance were measured using CT.

Abbreviations: AF, atrial fibrillation; aHT, arterial hypertension; AS, aortic stenosis; BPH, benign prostatic hyperplasia; CABG, coronary artery bypass grafting; CAD, coronary artery disease; CKD, chronic kidney disease; COPD, chronic obstructive pulmonary disease; CRT, cardiac resynchronization therapy; CT, computed tomography; DM-2, Type 2 diabetes mellitus; LAHB, left anterior hemiblock; LBBB, left bundle branch block; LCA, left coronary artery; LFLG, low flow low gradient; LVOT, left ventricular outflow tract; M, male; MR, mitral valve regurgitation; n.a., not available; NOAK, non-vitamin K oral anti-coagulant; NSR, normal sinus rhythm; NYHA, New York Heart Association; PCI, percutaneous coronary intervention; Pre-op ECG, pre-operative ecocardiogram; RBBB, right bundle branch block; RCA, right coronary artery; RHD, rheumatic heart disease; STS, The Society of Thoracic Surgeons operative risk score; TR, tricuspid regurgitation.

contralateral femoral side, the complication was considered not device-related and could be curatively treated.

During index hospital stay as well as up to 30-day follow-up, no stroke or death occurred.

Hemodynamic performance of the THV was found adequate in all cases. No patient showed more than mild paravalvular and none of the patients any transvalvular regurgitation.

In five patients, evidence of mild PVL could be observed after valve implantation in echo and/or angiography. This rate is significantly higher than the reported PVL 1+ rate of 6.7% in the Myval-1-study.<sup>8</sup> An explanation for this finding might be the underlying bicuspid anatomy and heavy calcium load in two of the cases, another potential explanation might be that prostheses sealing is more difficult in very large anatomy in general. The PVL could be eliminated by postdilatation in two of the cases. In case of the other three patients, postdilatation was not attempted as the impact of mild PVL on outcome seemed more acceptable than the potential risk of postdilatation. In our opinion, the indication for postdilatation in PVL  $\leq 2$  should be a case-by-case decision, which should be set under consideration of the expected patient activity and age, anatomical risk constellation, and the potential operability in case of a provoked complication.

Two patients required implantation of a permanent pacemaker after the procedure, resulting in a PPI rate of 20% in the series. With pre-existing right bundle branch block in one and bicuspid anatomy with massive calcium load of 4780 mm<sup>3</sup> in the other case, probability for postoperative pacemaker dependency had to be considered high in both cases.<sup>16,17</sup> Therefore, and in conjunction with the low rate of postprocedural pacemaker implantation in the Myval-1 trial, we do not necessarily consider this relatively high rate in our small series to be representative and of concern.

However, it should be noted that post-TAVR pacing rates in very large anatomies have not been studied in detail to date and certainly require larger series to obtain representative results. We can imagine that common sizing strategies that are mainly based on relative areal oversizing might be suboptimal in very large anatomy, as given percentages of oversizing result in larger absolute overlap of the devices to the patients' tissue. It is highly desirable that this issue is explored in larger studies to find the optimal strategies to balance the risks of inadequate paravalvular sealing and embolization of the device against rupture of the annulus and damage to the conduction system.

Data on the distribution of annular sizes in populations screened for TAVR are surprisingly sparse and published only in small multicenter studies,<sup>18</sup> which is why we analyzed the sizing data of a central European TAVR center to assess the need for extra-large TAVR prostheses. The data analysis showed a rate of about 1%–2% of patients who are not covered within the approval of the conventionally sized prostheses. Not surprisingly, male gender was dominating and bicuspid anatomy was observed in a relevant fraction of 31% of cases with anatomy above 680 mm<sup>2</sup>.

To overcome the sizing limitation of the conventional large devices to offer a treatment option for patients with too large

TABLE 2 Procedural details and outcome.

	Pat. 1	Pat. 2	Pat. 3	Pat. 4	Pat. 5	Pat. 6	Pat. 7	Pat. 8	Pat. 9	Pat. 10	Mean	SD
Chosen valve	32	32	32	32	32	32	32 with 38 mL (-2) <sup>a</sup>	32	32	32		
Valve oversizing, %	0.5	13	6.5	6	12	12.0	12.8	-1.9	-1.9	4.4		
Pre-BAV	None	Mammoth 25 mm	Mammoth 25 mm	Mammoth 25 mm	Mammoth 25 mm	Mammoth 25 mm	Mammoth 25 mm	Mammoth 25 mm	Mammoth 25 mm	Mammoth 25 mm		
Procedural time (skin to skin), min	42	48	39	69	126	55	85	130	115	50	75.9	35.7
Contrast use, mL	193	133	70	200	170	173	91	170	131	60	139.1	50.7
Radiation time, min:sec	20:00	12:30	11:18	26:08	41:43	23:00	18:25	15:06	18:00	10:10	19:38	08:49
Anesthesia	Conscious sedation	General	General	General	General	Conscious sedation	Conscious sedation	Conscious sedation	Conscious sedation	Conscious sedation		
Sheath for TAVI access	Python 14F	Python 14F	Python 14F	Python 14F	Python 14F	Python 14F	Python 14F	Python 14F	Python 14F	Python 14F		
Access site closure	1 Proglide + 8F Angioseal	Manta 18F	Manta 18F	2 Proglide	2 Proglide	2 Proglide	2 Proglide	1 Proglide	2 Proglide	2 Proglide		
VARC-2 device success	Yes	Yes	Yes	Yes	Yes	Yes	Yes	Yes	Yes	Yes		
Procedural events	None	None	Two shocks were delivered by the ICD during valve implantation. Valve height could be corrected within rapid overpacing.	None	Postdilatation performed	None	None	None	new LBBB	None		
In-hospital events <sup>b</sup>	None	Implantation of permanent pacemaker day 2 due to intermittent AV-Block II° (Wenckebach)	Diffuse retroperitoneal hematoma on contralateral side of TAVI access due to failure of 6F Angioseal at pigtail sheath	Permanent Pacemaker implantation for bradyarrhythmia. Hemoglobin drop without overt bleeding (12.1-9.9). Postoperative infection most likely due to cruric ulcer	None	Pseudoaneurysmal at access site solved by manual compression.	Hemoglobin drop during hospitalization without overt bleeding (12.4-8.9 g/dL). No transfusion necessary.	None	LBBB persisted till discharge. No pacemaker indication	None		

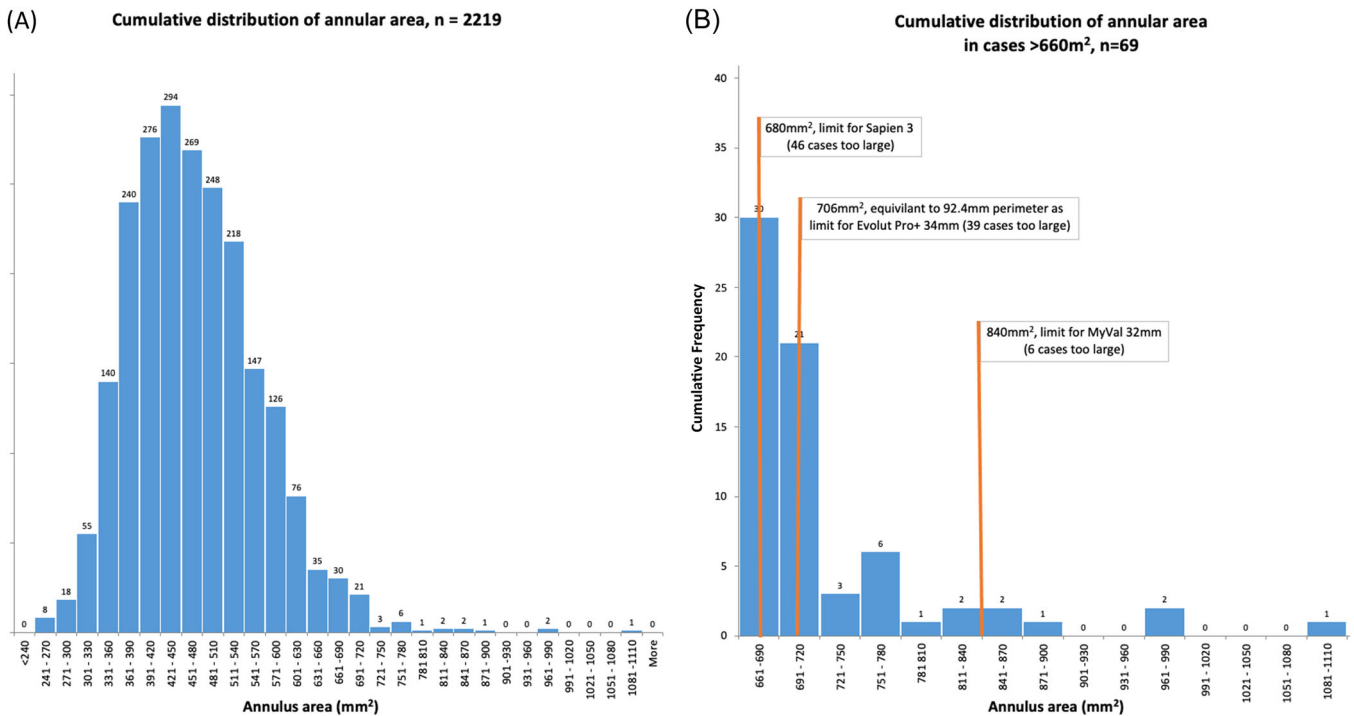
TABLE 2 (Continued)

	Pat. 1	Pat. 2	Pat. 3	Pat. 4	Pat. 5	Pat. 6	Pat. 7	Pat. 8	Pat. 9	Pat. 10	Mean	SD
Paravalvular regurgitation	None	Mild	None	Mild	None	None	None	None	None	Mild		
Transvalvular regurgitation	None	None	None	None	None	None	None	None	Mild	None		
Peak aortic valve gradient, mmHg	3.2 <sup>b</sup>	12	8	19	18	7	14	8	16	10	12.4	4.5
Mean aortic valve gradient, mmHg	4.8 <sup>b</sup>	7	3	9	6	4	5.6	5	9	4	5.8	2.1
LVEF, %	30	49	40	55	60	55	43	67	63	45	50.7	11.4
Aortic valve area, cm <sup>2</sup>	3.2	2.3	n.a.	2.8	2.2	5.1	2.6	n.a.	n.a.	n.a.	3.3	1.6
Events in 30d FU	None	None	None	None	None	None	None	None	None	None	None	None

Abbreviations: FU, follow-up; ICD, implantable cardioverter-defibrillator; LBBB, left bundle branch block; LVEF, left ventricular ejection fraction; LVOT, left ventricular outflow tract; TAVI, pre-BAV, balloon aortic valvuloplasty prior to TAVI implantation; transcatheter aortic valve implantation; VARC-2, Valve Academic Research Consortium-2.

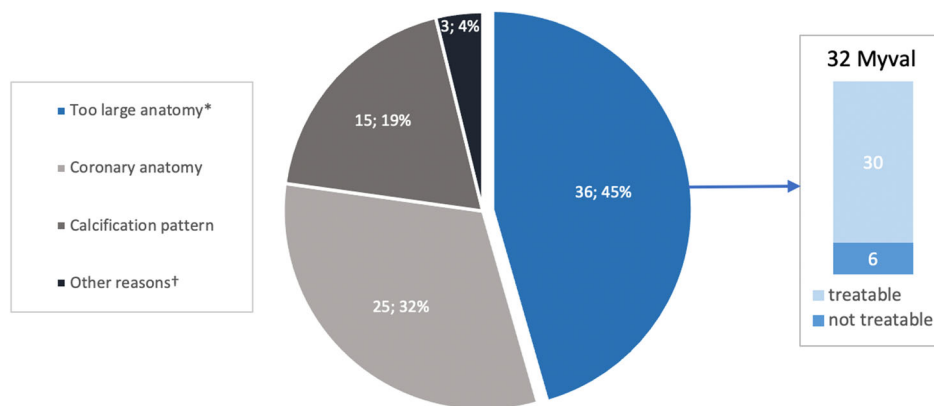
<sup>a</sup>For Patient 7, the balloon of the implantation device was used with 2 mL less than the nominal filling volume to achieve optimized oversizing for the annular area 712 mm<sup>2</sup>.

<sup>b</sup>Postoperative gradients were measured in transthoracic echocardiography in all cases, except of Patient 1, where invasive measurement was performed.



**FIGURE 3** Distribution of annular area. (A) Annular areas of the all-comer cohort consisting of 2219 patients screened for transcatheter aortic valve implantation (TAVI) at a central European site. (B) Focused view on patients with an annular area larger than 660 mm<sup>2</sup>. Orange indicator lines represent upper sizing limits according to manufacturer's instructions for use. A total of 36 patients (1.6% of all screened patients) was too large for conventional treatment options using the 29 mm Sapien 3 or Evolut Pro 34 mm devices. This rate could be dropped to six patients 0.27% using the 32 mm MyVal device. [Color figure can be viewed at [wileyonlinelibrary.com](https://onlinelibrary.wiley.com/doi/10.1111/1801-1801)]

#### Reasons for anatomical contraindications in 2219 screened patients (82 patients with contraindications)



**FIGURE 4** Anatomical contraindications for transcatheter aortic valve implantation (TAVI). In the assessment of CT scans from 2219 patients, anatomical contraindications were found in 82 cases. Too large anatomy for conventional transcatheter aortic valve replacement (TAVR) devices was found in 36 patients as the most frequent contraindication for TAVR. Using the 32 mm MyVal device, 30 of the 36 patients (83%) could have been treated within the intended sizing range. \*Patients with annular area larger than 680 mm<sup>2</sup> and perimeter larger than 94.2 mm according to the sizing ranges for 29 mm Sapien 3 and 34 mm Evolut Pro †other reasons are cases with contraindications caused by mitral valve prosthesis, left ventricular outflow tract (LVOT) aneurysm and protruding coronary ostial stent. [Color figure can be viewed at [wileyonlinelibrary.com](https://onlinelibrary.wiley.com/doi/10.1111/1801-1801)]

anatomy, off-label use of the 29 mm Sapien 3 and Evolut R devices have been performed and published in different retrospective studies.

Shivaraju et al.<sup>19</sup> observed that overexpansion (~11%–13%) of the SAPIEN-3 can be considered as an effective approach to accommodate larger annular sizes. The authors describe that oversizing the Sapien 3 device with 2–4 mL of additional volume for the delivery balloon might be an option to increase the maximum sizing range of the 29 mm device up to 740 mm<sup>2</sup>. Next to expanding the upper sizing limit of the large valve size, the authors also state that this technique could be an option to optimize the valve sizes for patients with borderline anatomy that is in between to sizes. In CT studies that were performed after the overexpansion, the in- and outflow-portion of the stent appeared flared and were described about 10% larger than the valve's nominal size. Although they did not observe this in their patient cohort, the authors state that this might have negative impact on leaflet coaptation and might lead to central insufficiency. Subsequent clinical studies demonstrated encouraging clinical outcomes of TAVR for treatment of large aortic annulus (>683 mm<sup>2</sup>) with overexpansion of the 29 mm SAPIEN-3 THV.<sup>20–23</sup> Published data on use of the Evolut R in extra-large anatomy is limited to the TAVR-LARGE registry<sup>24</sup> to our best knowledge. The study describes the usage of both the Sapien 3 and Evolut R prosthesis in its extra-large subcohort of 125 patients with an average annulus area of 702 mm<sup>2</sup> and the regular “on-label” cohort with average annular area of 617 mm<sup>2</sup>. The authors conclude that both devices can be used with similar results to regular large anatomy in the extra-large patients.

Nevertheless, mean aortic area of the aforementioned studies varies between 698 and 721 mm<sup>2</sup>, and publications that focus on patients with extremely large aortic annulus (aortic area >740 mm<sup>2</sup>) is limited to very small case series.<sup>25</sup> Although the above studies are positive about the clinical performance of Sapien 3 THV for treatment in the “off-label” indication, all authors state that generalization of results requires careful consideration of retrospective analysis and limited patient numbers.

The first prospectively collected and monitored trial cohort that includes patients with extra-large anatomy is the nested XL registry of the currently enrolling LANDMARK trial ([ClinicalTrials.gov](https://clinicaltrials.gov/ct2/show/study/NCT04275726) NCT04275726). Data of this trial will hopefully bring some evidence in this field.

Further concerns about the concept of overexpansion of conventional sized prosthesis have arisen by ex vivo bench testing. Sathananthan et al.<sup>26</sup> report mechanical valve dysfunction after bench-testing overexpansion in some of the investigated Sapien 3 prostheses. In this bench test, overexpansion was tested in a small number of prostheses with up to 3 mL of additional volume. The authors conclude that excessive overexpansion may be associated with impaired hydrodynamic function, acute leaflet failure, and reduced durability.

Results of ex vivo studies further raised concern of long-term durability of overexpanded THV in consideration with tissue damage of the bioleaflets. Sellers et al.<sup>27</sup> performed an ex vivo study to determine the impact of overexpansion on leaflet ultrastructure across different valve sizes (23, 26, and 29 mm). The authors observed

ultrastructure damage to leaflets as evident by significant increase in the entropy of fibrillar collagen (both on aortic and ventricular aspect of the leaflets), leaflet thinning and increased density of tissue within the leaflet matrix in overexpanded valves compared with the nominally expanded control valves. Because of the limited follow-up periods of 1 year or less after implantation of overexpanded TAVR prostheses, the true impact of these findings cannot yet be assessed in clinical data.

An editorial comment on one of the retrospective studies summarizes the concerns about off-label usage of overexpanded prostheses.<sup>28</sup> The author concludes that future THVs should be designed to function optimally at a wide range of conditions to accommodate the variability in patient anatomy.

On the other hand, no larger trials are available for the new Myval device. In contrast to Sapien valves only preliminary experience with the very large anatomy exists, as summarized herein.

Therefore, the large amount of data with Sapien valves in normal anatomy and comparably also larger experience with its off-label oversizing in patients with anatomy up to about 720 mm<sup>2</sup> needs to be balanced against an on-label application with only preliminary experience.

The first prospectively enrolled and monitored study cohort to include patients with extra-large anatomy is the “Nested XL Registry” of the currently enrolling LANDMARK study ([ClinicalTrials.gov](https://clinicaltrials.gov/ct2/show/study/NCT04275726) NCT04275726). The data from this study will hopefully provide some insights on this topic that has received no attention in prospective multicentric trials until now.

The Myval THV series (Meril Life Sciences Pvt. Ltd) has a vast range of THV sizes (traditional sizes: 20, 23, 26, and 29 mm; intermediate sizes: 21.5, 24.5, and 27.5 mm; and extra-large sizes: 30.5 and 32 mm). The expanded size matrix of the Myval THV especially at the upper range of the portfolio might therefore overcome these concerns in the vast majority of patients.

## 5 | LIMITATIONS

Our study carries inherent limitations of the retrospective observational study. Acute clinical performance of the device was evaluated in a small number of patients at short-term follow-up. Valve performance was reported by the participating sites without core-lab verification of the underlying imaging. There was no systematic monitoring of reported data. The evaluation of valve size suitability was performed in a monocentric central European cohort. It can be assumed that annulus sizes and thus anatomical contraindications vary in different ethnic groups, which is why the results may vary globally.

## 6 | CONCLUSION

The present study shows promising first results regarding the performance of the 32 mm Myval THV in a cohort of patients with extremely large annular anatomy in a real-world scenario. Although

the frequency of extra-large anatomies is relatively low and the examined prostheses sizes can be considered niche devices, it is desirable that TAVI prosthesis manufacturers address larger anatomies when developing future models to allow optimal treatment for more patients.

## 7 | IMPACT ON DAILY PRACTICE

With the availability of this extremely large prosthesis, a previously untreatable cohort of potential patients with too large anatomy could benefit from the advantages of the minimally invasive TAVR therapy.

### CONFLICT OF INTEREST STATEMENT

Andreas Holzamer: Consultant (Proctor) for Meril. Francesco Bedogni: Consultant (Proctor) for Meril. Pieter van Wyk: Nothing to declare related to the content of this manuscript. Parag Barwad: Nothing to declare related to the content of this manuscript. Marcin Protasiewicz: Consultant (Proctor) for Meril. Alfonso Ielasi: Nothing to declare related to the content of this manuscript. Luis Nombela-Franco: Nothing to declare related to the content of this manuscript. Tim Seidler: Nothing to declare related to the content of this manuscript.

### ACKNOWLEDGMENT

Open Access funding enabled and organized by Projekt DEAL.

### DATA AVAILABILITY STATEMENT

The data that support the findings of this study are available from the corresponding author, Andreas Holzamer, upon reasonable request.

### ORCID

Andreas Holzamer  <https://orcid.org/0000-0002-1838-3033>

Francesco Bedogni  <https://orcid.org/0000-0002-4975-6605>

Parag Barwad  <https://orcid.org/0000-0001-7702-325X>

Alfonso Ielasi  <https://orcid.org/0000-0002-5982-1669>

Luis Nombela-Franco  <https://orcid.org/0000-0003-3438-8907>

### REFERENCES

- Leon MB, Smith CR, Mack MJ, et al. Transcatheter or surgical aortic-valve replacement in intermediate-risk patients. *N Engl J Med*. 2016;374(17):1609-1620.
- Kapadia SR, Leon MB, Makkar RR, et al. 5-year outcomes of transcatheter aortic valve replacement compared with standard treatment for patients with inoperable aortic stenosis (PARTNER 1): a randomised controlled trial. *Lancet*. 2015;385(9986):2485-2491.
- Mack MJ, Leon MB, Smith CR, et al. 5-year outcomes of transcatheter aortic valve replacement or surgical aortic valve replacement for high surgical risk patients with aortic stenosis (PARTNER 1): a randomised controlled trial. *Lancet*. 2015;385(9986):2477-2484.
- Mack MJ, Leon MB, Thourani VH, et al. Transcatheter aortic-valve replacement with a balloon-expandable valve in low-risk patients. *N Engl J Med*. 2019;380(18):1695-1705.
- Popma JJ, Deeb GM, Yakubov SJ, et al. Transcatheter aortic-valve replacement with a self-expanding valve in low-risk patients. *N Engl J Med*. 2019;380(18):1706-1715.
- Serruys PW, Modolo R, Reardon M, et al. One-year outcomes of patients with severe aortic stenosis and an STS PROM of less than three percent in the SURTAVI trial. *EuroIntervention*. 2018;14(8):877-883.
- Rao RS, Sharma SK, Chandra P, et al. Evaluation of balloon expandable transcatheter heart valve in the treatment of severe symptomatic native aortic stenosis: the first-in-human Myval-1 study. *Struct Heart*. 2020;4(sup1):188-189.
- Kappetein AP, Head SJ, Genereux P, et al. Updated standardized endpoint definitions for transcatheter aortic valve implantation: the Valve Academic Research Consortium-2 consensus document (VARC-2). *Eur J Cardiothorac Surg*. 2012;42(5):S45-S60. doi:10.1093/ejcts/ezs533
- Achenbach S, Delgado V, Hausleiter J, Schoenhagen P, Min JK, Leipsic JA. SCCT expert consensus document on computed tomography imaging before transcatheter aortic valve implantation (TAVI)/transcatheter aortic valve replacement (TAVR). *J Cardiovasc Computed Tomography*. 2012;6(6):366-380. doi:10.1016/j.jcct.2012.11.002
- Sharma SK, Rao RS, Chopra M, Sonawane A, Jose J, Sengottuvelu G. Myval transcatheter heart valve system in the treatment of severe symptomatic aortic stenosis. *Future Cardiol*. 2020;17(1):73-80.
- Drakopoulou M, Toutouzas K, Stathogiannis K, et al. Impact of valve over-sizing after transcatheter aortic valve implantation with a self-expanding valve: a multislice computed tomography study. *J Invasive Cardiol*. 2019;31(5):76.
- Chen S, Chau KH, Nazif TM. The incidence and impact of cardiac conduction disturbances after transcatheter aortic valve replacement. *Ann Cardiothorac Surg*. 2020;9(6):452-467. doi:10.21037/acs-2020-av-23
- Schofer N, Deuschl F, Rübsamen N, et al. Prosthesis-patient mismatch after transcatheter aortic valve implantation: prevalence and prognostic impact with respect to baseline left ventricular function. *EuroIntervention*. 2019;14(16):1648-1655. doi:10.4244/EIJ-D-18-00827
- Barbanti B. Avoiding coronary occlusion and root rupture in TAVI - the role of pre-procedural imaging and prosthesis selection. *Interv Cardiol Rev*. 2015;10(2):94-97. doi:10.15420/icr.2015.10.2.94
- Kim WK, Schäfer U, Tchetché D, et al. Incidence and outcome of peri-procedural transcatheter heart valve embolization and migration: the TRAVEL registry (Transcatheter HeArt Valve Embolization and Migration). *Eur Heart J*. 2019;40(38):3156-3165. doi:10.1093/eurheartj/ehz429
- Husser O, Pellegrini C, Kim WK, et al. Transcatheter valve SELECTION in patients with right bundle branch block and impact on pacemaker implantations. *JACC Cardiovasc Interv*. 2019;12(18):1781-1793. doi:10.1016/j.jcin.2019.05.055
- Sharma E, McCauley B, Ghosalkar DS, et al. Aortic valve calcification as a predictor of post-transcatheter aortic valve replacement pacemaker dependence. *Cardiol Res*. 2020;11(3):155-167. doi:10.14740/cr1011
- John D, Latsios G, Yucel S, et al. TCT-760: numerous patients fail the aortic annulus criteria in transcatheter aortic valve implantation. *J Am Coll Cardiol*. 2011;58(20 supplement):B202-B203.
- Shivaraju A, Kodali S, Thilo C, et al. Overexpansion of the SAPIEN 3 transcatheter heart valve: a feasibility study. *JACC Cardiovasc Interv*. 2015;8(15):2041-2043.
- Schaefer A, Linder M, Treede H, et al. Applicability of next generation balloon-expandable transcatheter heart valves in aortic annuli exceeding formally approved dimensions. *Clin Res Cardiol*. 2016;105(7):585-591.

21. Zaid S, Kamioka N, Terre J, et al. 1-year results of transcatheter aortic valve replacement in extremely large annuli >683 mm<sup>2</sup> with Edwards Sapien 3 valve: a multicenter experience. *JACC*. 2019;73(9 supplement 1):1377.
22. Barr P, Ormiston J, Stewart J, Nand P, Ramanathan T, Webster M. Transcatheter aortic valve implantation in patients with a large aortic annulus. *Heart Lung Circ*. 2018;27(3):11.
23. Mathur M, McCabe JM, Aldea G, Pal J, Don CW. Overexpansion of the 29 mm SAPIEN 3 transcatheter heart valve in patients with large aortic annuli (area >683 mm<sup>2</sup>): a case series. *Catheter Cardiovasc Interv*. 2018;91(6):1149-1156.
24. Armijo G, Tang GHL, Kooistra N, et al. Third-generation balloon and self-expandable valves for aortic stenosis in large and extra-large aortic annuli from the TAVR-LARGE registry. *Circ Cardiovasc Interv*. 2020;13(8):e009047. doi:10.1161/CIRCINTERVENTIONS.120.009047
25. Sengupta A, Zaid S, Kamioka N, et al. Mid-term outcomes of transcatheter aortic valve replacement in extremely large annuli with Edwards SAPIEN 3 valve. *JACC Cardiovasc Interv*. 2020;13(2):210-216. doi:10.1016/j.jcin.2019.08.042
26. Sathanathan J, Sellers S, Barlow A, et al. Overexpansion of the SAPIEN 3 transcatheter heart valve. *JACC Cardiovasc Interv*. 2018;11(17):1696-1705. doi:10.1016/j.jcin.2018.06.027
27. Sellers SL, Sathanathan J, Bouchareb R, et al. Impact of overexpansion on SAPIEN 3 transcatheter heart valve pericardial leaflets. *Struct Heart*. 2020;4(3):214-220.
28. Wood DA, Sathanathan J. Non-nominal deployment of transcatheter heart valves. *JACC Cardiovasc Interv*. 2020;13(2):217-218.

**How to cite this article:** Holzamer A, Bedogni F, van Wyk P, et al. Performance of the 32 mm Myval transcatheter heart valve for treatment of aortic stenosis in patients with extremely large aortic annuli in real-world scenario: first global, multicenter experience. *Catheter Cardiovasc Interv*. 2023;102:1364-1375. doi:10.1002/ccd.30820