

# Successful management of left main coronary artery obstruction following transcatheter aortic valve implantation

DR Viveka Kumar\*, DR Vivek Kumar

*Institution at which work was performed Max Super Speciality Hospital, Saket, New Delhi, 110017, India*

## ARTICLE INFO

### Article history:

Received 16 May 2019

Accepted 23 June 2020

### Keywords:

Coronary ostial occlusion

Left main coronary artery

Percutaneous coronary intervention

Transcatheter aortic valve replacement

TAVR complications

## ABSTRACT

TAVR, the preferred treatment for severe aortic stenosis in intermediate to high-risk patients is rarely complicated with coronary obstruction. We present successful management of this rare but potentially fatal procedural complication, by percutaneous coronary intervention, following TAVR. Additionally, emphasize on considering individual leaflet length and bulkiness while deciding on coronary protection prior TAVR.

© 2020 Published by Elsevier B.V. on behalf of Cardiological Society of India. This is an open access article under the CC BY-NC-ND license (<http://creativecommons.org/licenses/by-nc-nd/4.0/>).

## Introduction

Transcatheter aortic valve replacement (TAVR) has been accepted as the treatment of choice for severe symptomatic native aortic stenosis in high and intermediate risk patients.<sup>1,2</sup> It is necessary to recognize the unusual complications of the procedure apart from frequent risks. Coronary obstruction (CO) is among one of the fatal infrequent procedural complications of TAVR. Although the reported incidence of coronary obstruction for native aortic valve stenosis is very low (<1%) in the setting of TAVR, it is associated with mortality of approximately 50%.<sup>3,4</sup> Mortality even exceeds 20% following successful rescue with percutaneous coronary intervention.<sup>5</sup> Hence, instantaneous and appropriate coronary intervention is required to resolve the situation accompanied by prudent understanding of risk-factors that lead to coronary obstruction. We present a case of left main coronary artery obstruction, manifested as a complication of TAVR in surgically high-risk patient. It is noteworthy that the patient did not have any of the well-documented risk factors. Hence, coronary protection was not pre-planned during TAVR. However, this fatal complication of TAVR was successfully managed with the implantation of stent.

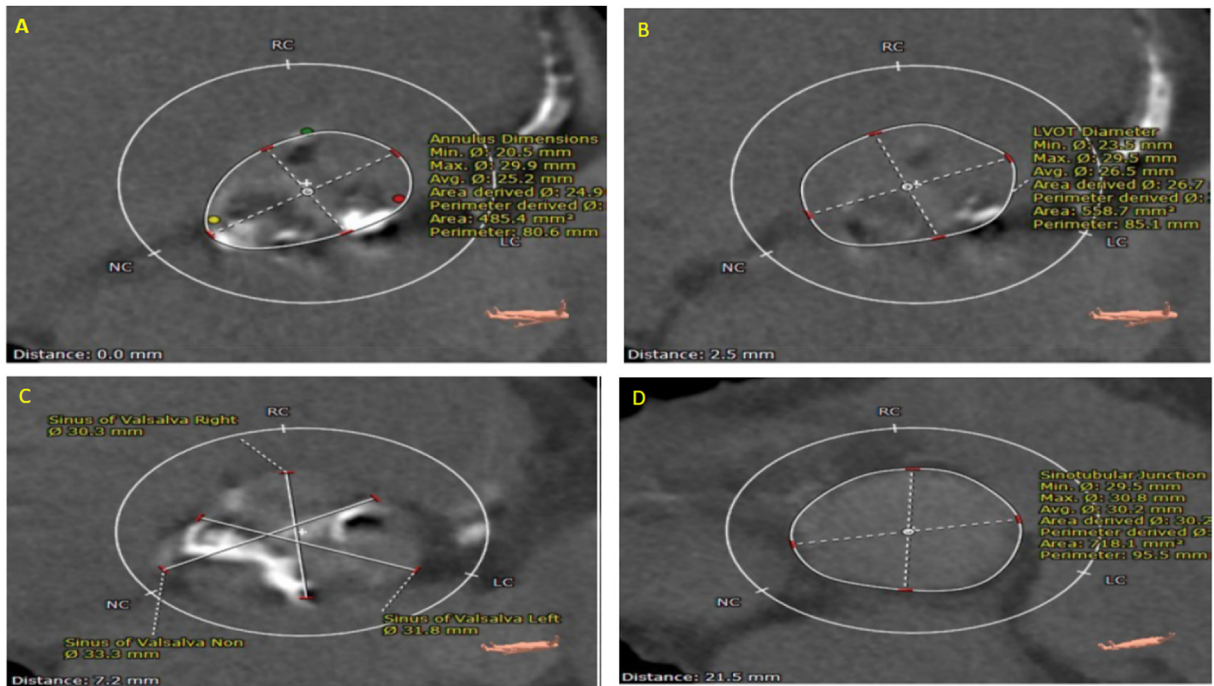
## Case-report

A 73-year-old male presented with severe symptomatic aortic stenosis (AS) (New York Heart Association Functional class-III) along with dyspnea for 7 days. He had a history of recurrent hospital admission since last 2 months due to heart failure. He was a known case of diabetes mellitus, hypertension, and coronary artery disease, with previous angioplasty to left circumflex artery. Trans-thoracic echocardiography showed severe AS (maximum/mean peak aortic gradient = 67/41 mmHg) with preserved systolic function. Calculated Society of Thoracic Surgeons (STS) risk score was 7.1% with mild frailty. Eligibility for TAVR was confirmed by the Heart Team. After stabilization, contrast computed tomography (CT) was performed. The heights of left and right coronary artery were 11.3 mm and 12.8 mm, respectively. Aortic annulus area and perimeter were 485.4 mm<sup>2</sup> and 80.6 mm, respectively. Diameters of sinus of Valsalva, sinotubular junction and LVOT were 31.8 mm, 30.3 mm and 26.5 mm respectively. The assessment revealed moderate calcification of aortic annulus and leaflets. The Myval™ (Meril Life Sciences Pvt. Ltd., India) balloon expandable transcatheter heart valve (THV) of size 26 mm was planned to be deployed and left femoral artery was opted for access (see Fig. 1).

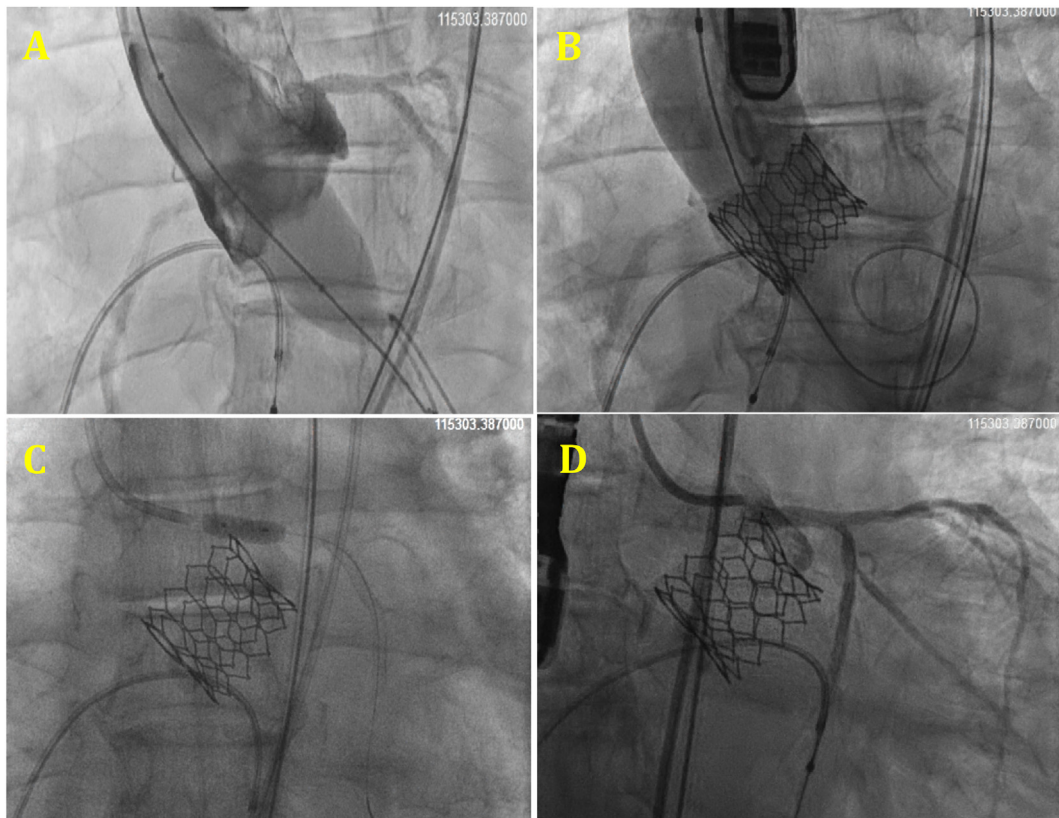
After induction of general anesthesia, the procedure was performed under the guidance of Transesophageal echocardiography (TEE). In a transfemoral approach, 22F introducer sheath was placed in the left femoral artery and another 6F sheath in the right femoral artery (RFA). After successfully crossing the aortic valve and placing Confida™ wire (Medtronic Inc., Minnesota, USA) at left

\* Corresponding author. Max Super Speciality Hospital, Saket, New Delhi, 110017, India.

E-mail addresses: [viveka.kumar@maxhealthcare.com](mailto:viveka.kumar@maxhealthcare.com) (D.V. Kumar), [drvivek@gmail.com](mailto:drvivek@gmail.com) (D.V. Kumar).



**Fig. 1.** Cardiac computed tomography angiography showed (A) annular area of 485.4mm<sup>2</sup> and perimeter of 80.6mm; (B) LVOT size of 26.5mm; (C) sinus of Valsalva size of 31.8 mm; (D) sinotubular junction size of 30.3mm.



**Fig. 2.** Coronary angiogram showed (A) Balloon aortic valvuloplasty (BAV) with no coronary flow obstruction. (B) Myval deployed – obstruction observed in Left coronary artery. (C) Percutaneous coronary intervention (PCI) in relation to LCA (D) Post PCI – LCA low restored.

ventricular apex, balloon aortic valvuloplasty was performed with 22mm Z-MED™ (B. Braun Interventional Systems Inc.

Pennsylvania, USA) balloon. This was followed by the deployment of Myvalve THV of size 26 mm at nominal volume. Immediately,

after valve deployment, patient went into severe hypotension followed by ventricular tachycardia for which cardiopulmonary resuscitation (CPR) was required. TEE showed new severe global hypokinesia without any evidence of pericardial effusion. Aortic root angiography revealed left main (LM) artery occlusion, which required immediate intervention. LM occlusion was successfully crossed with a WHISPER™ (Abbott) guidewire through RFA access. A drug-eluting stent was deployed ( $4 \times 15\text{mm}$ ) to treat LM occlusion followed by proximal optimization technique (using  $5 \times 9\text{mm}$  balloon) and proximal flaring. Coronary circulation was restored successfully (Fig. 2&) with improvement of hemodynamics and normal LV contractility. Femoral artery access was closed with Perclose Proglide™ closure device.

## Discussion

Obstruction of the coronary arteries during the valve implantation is uncommon, but a well-documented and life-threatening complication of TAVR. Major risk factors contributing to coronary obstruction during TAVR are coronary artery orifice close to aortic annulus, narrow sinus of Valsalva, valve in valve intervention, and severity of valve calcification. In the patients with aforementioned risk factors, undeployed stent is parked in respective coronary artery over a guide wire for coronary protection so that it can be expanded when blood flow in the coronary artery is compromised.<sup>3,5</sup> Apart from calcification status of the valve, associated bulkiness of the leaflets due to presence of heavy calcium nodules has also been identified as a potential risk factor. In addition, data from few registries prospect the involvement of balloon-expandable valve implantation as factor predisposing to coronary obstruction. Majority of cases involve obstruction of left coronary artery perhaps because left coronary ostium at a lesser distance from aortic annulus, several pre-procedural and technical aspects have been described to identify those patients who are at increased risk of coronary obstruction during TAVR. As mentioned previously, distance between coronary ostia and aortic annulus has a major contribution towards this complication, and the recommended cut-off of  $\leq 10\text{mm}$  is established to be an alerting criteria. Furthermore, narrow aortic root with smaller sinus of Valsalva diameters provide insufficient space for leaflet accommodation and may lead to

coronary ostia occlusion.<sup>6</sup> None of the above recommended factors stood true for our case, with both the coronaries at a distance of  $>10\text{mm}$  from aortic annulus and a well roomed sinus of Valsalva diameter. Hence, coronary obstruction was not anticipated beforehand in this case, but on the hindsight it was realized that even after moderate overall valve calcification, the left coronary cusp leaflet had sizeable calcium content, which may have contributed to the obstruction of left main artery. Hence, as coronary obstruction mitigation strategies are largely limited to awareness and avoidance, the operators should consider possibility of coronary obstruction for bulky and lengthy leaflets even with presumably safer coronary heights.

## Conclusion

This case-report highlights the need of contemplating coronary protection with preemptive technique during TAVR in patients with bulky and lengthy leaflets to avoid the risk of coronary artery obstruction, because not only substantial amount of total calcium but individual leaflet calcium can also contribute to coronary obstruction more so with coronary ostia at considerable distance ( $>10\text{mm}$ ) from aortic annulus.

## References

1. Leon MB, Smith CR, Mack M, et al. Transcatheter aortic-valve implantation for aortic stenosis in patients who cannot undergo surgery. *N Engl J Med*. 2010;363(17):1597–1607.
2. Salemi A, Worku BM. Standard imaging techniques in transcatheter aortic valve replacement. *J Thorac Dis*. 2017;9(suppl 4): S289–s98.
3. Dvir D, Leipsic J, Blanke P, et al. Coronary obstruction in transcatheter aortic valve-in-valve implantation: preprocedural evaluation, device selection, protection, and treatment. *Circ Cardiovasc Inter*. 2015;8(1).
4. Arai T, Lefevre T, Hovasse T, et al. Incidence and predictors of coronary obstruction following transcatheter aortic valve implantation in the real world. *Cathet Cardiovasc Interv Off J Soc Cardiac Angiogr Inter*. 2017;90(7):1192–1197.
5. Ribeiro HB, Webb JG, Makkar RR, et al. Predictive factors, management, and clinical outcomes of coronary obstruction following transcatheter aortic valve implantation: insights from a large multicenter registry. *J Am Coll Cardiol*. 2013;62(17):1552–1562.
6. Ribeiro HB, Nombela-Franco L, Urena M, et al. Coronary obstruction following transcatheter aortic valve implantation: a systematic review. *JACC Cardiovasc Interv*. 2013;6(5):452–461.